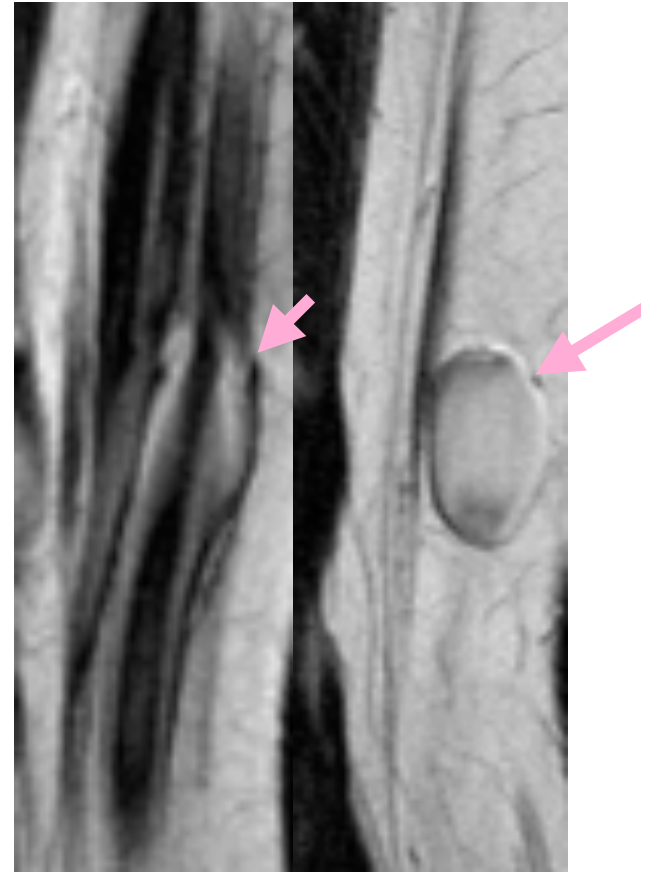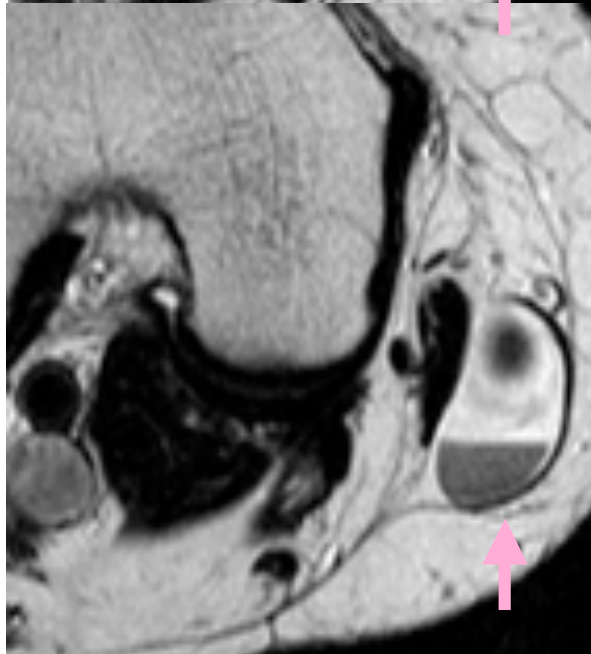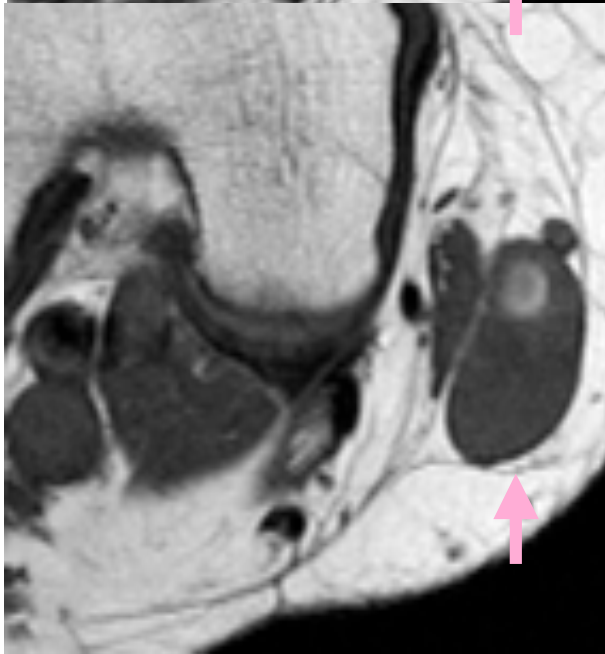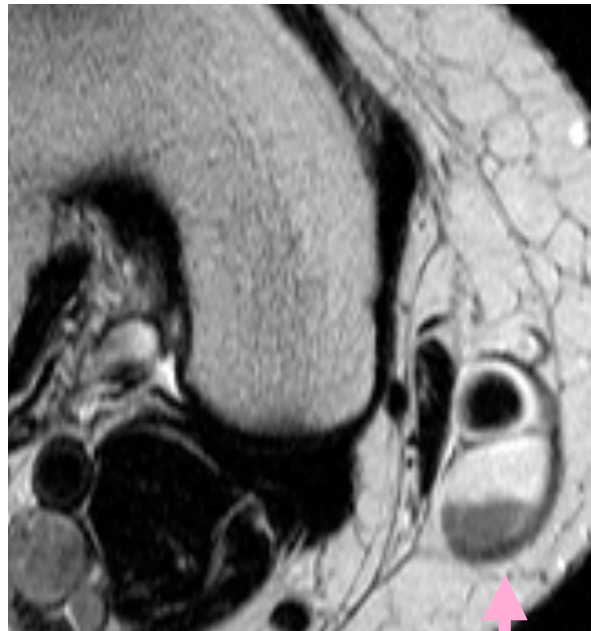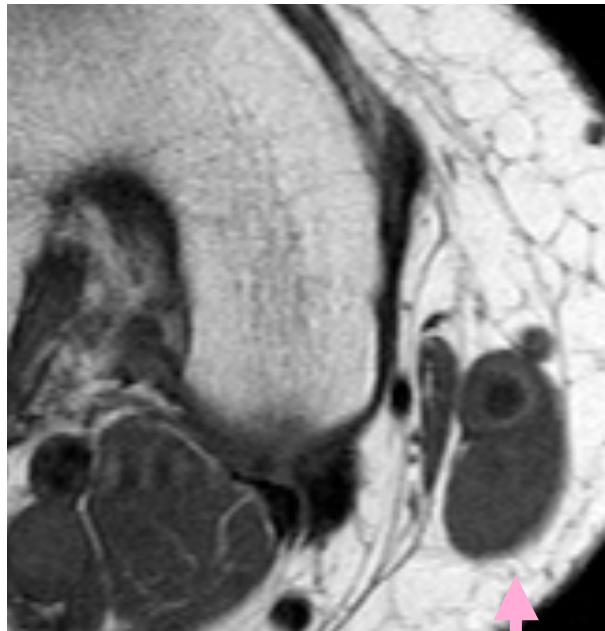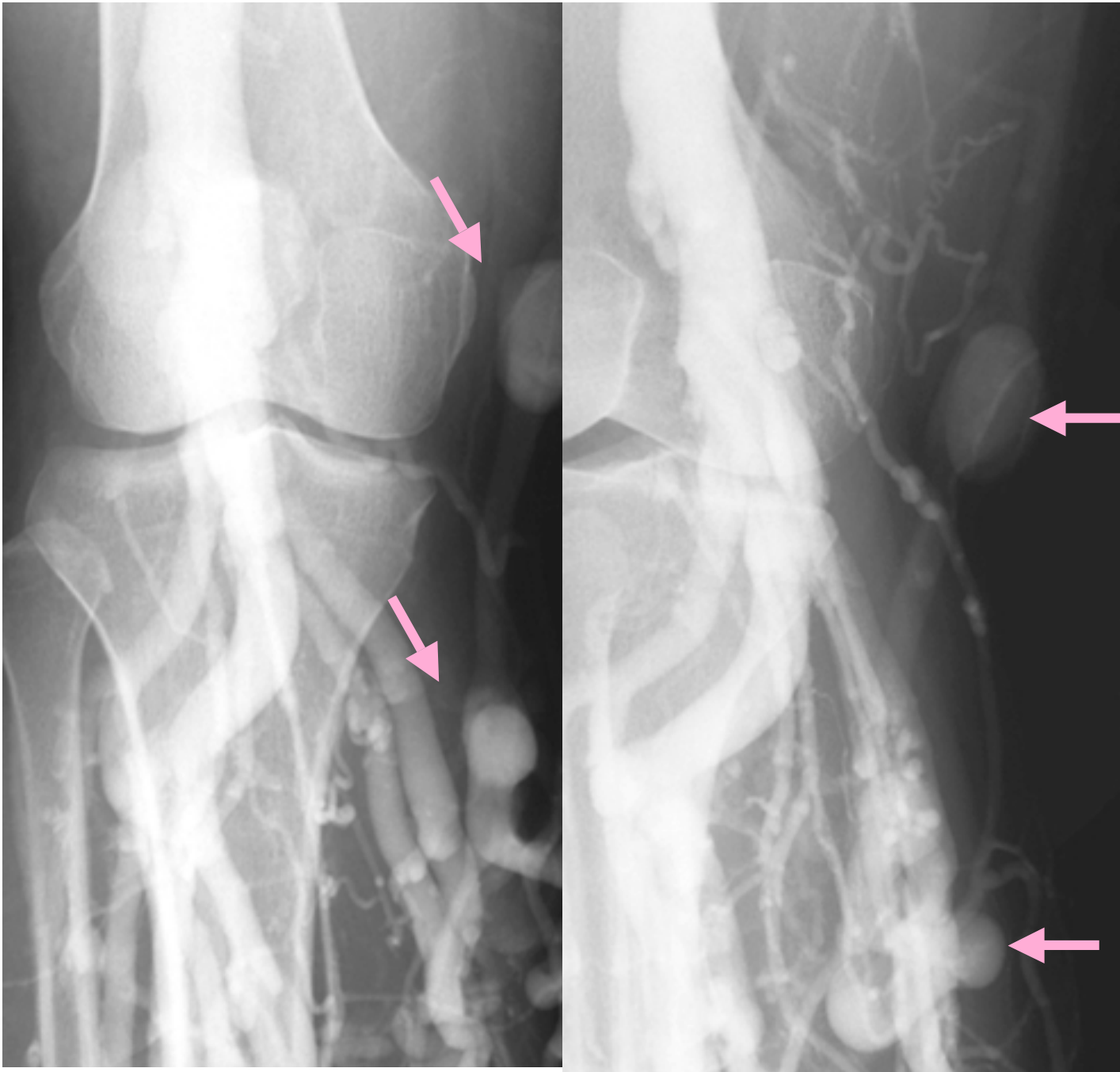


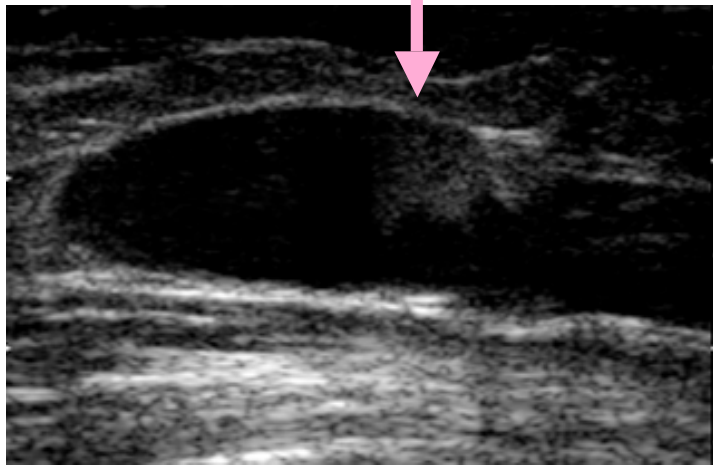
T1WI 水平断

膝部单纯MRI

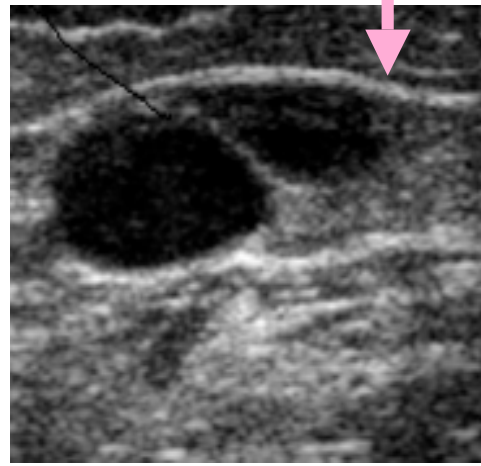
T2WI 水平断・
冠状断



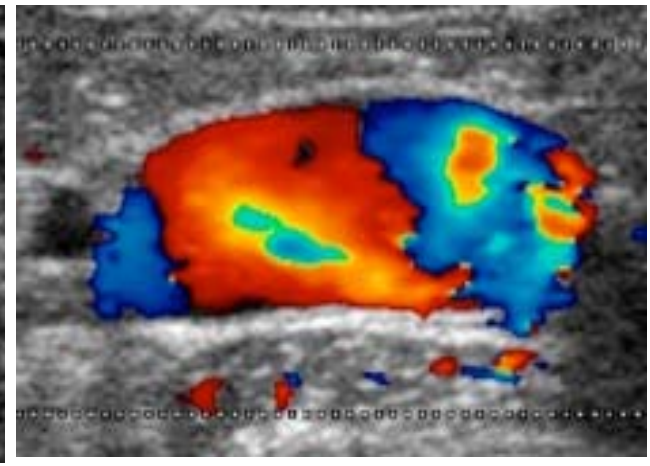
VENOGRAPHY



矢状断像



水平断像



壁肥厚や瘤内血栓なし

US