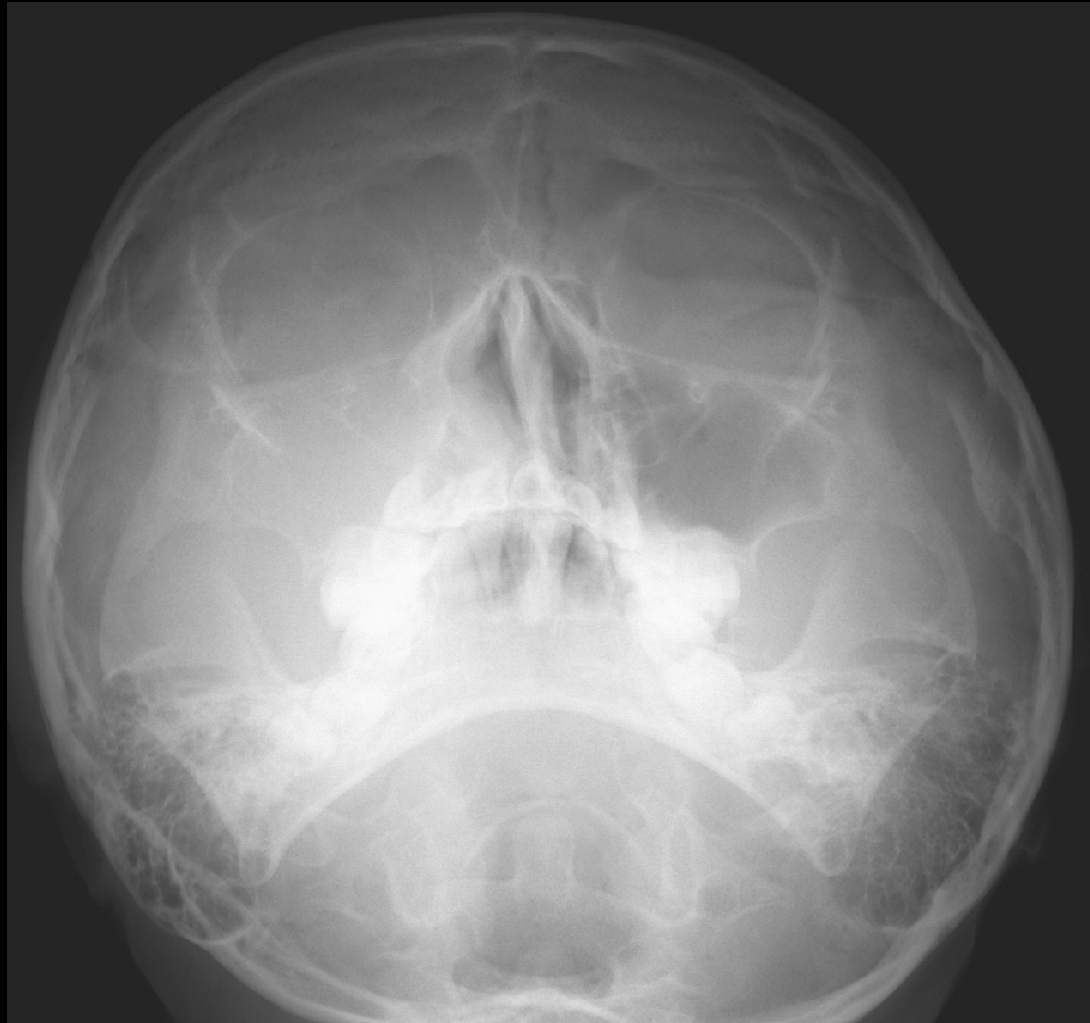
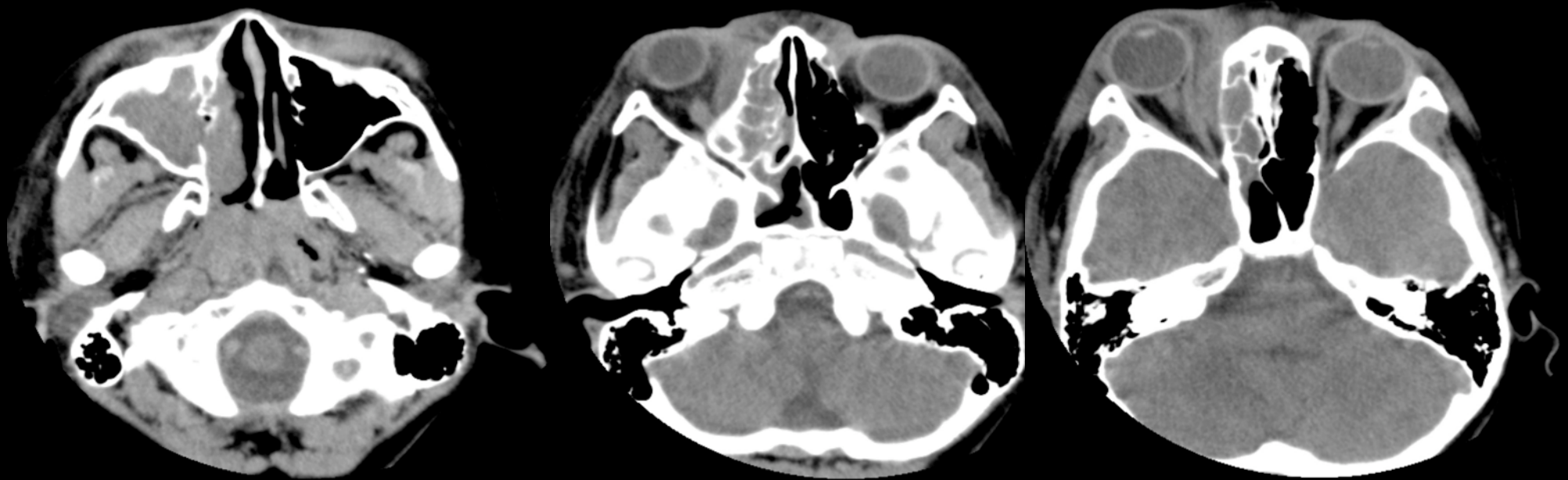


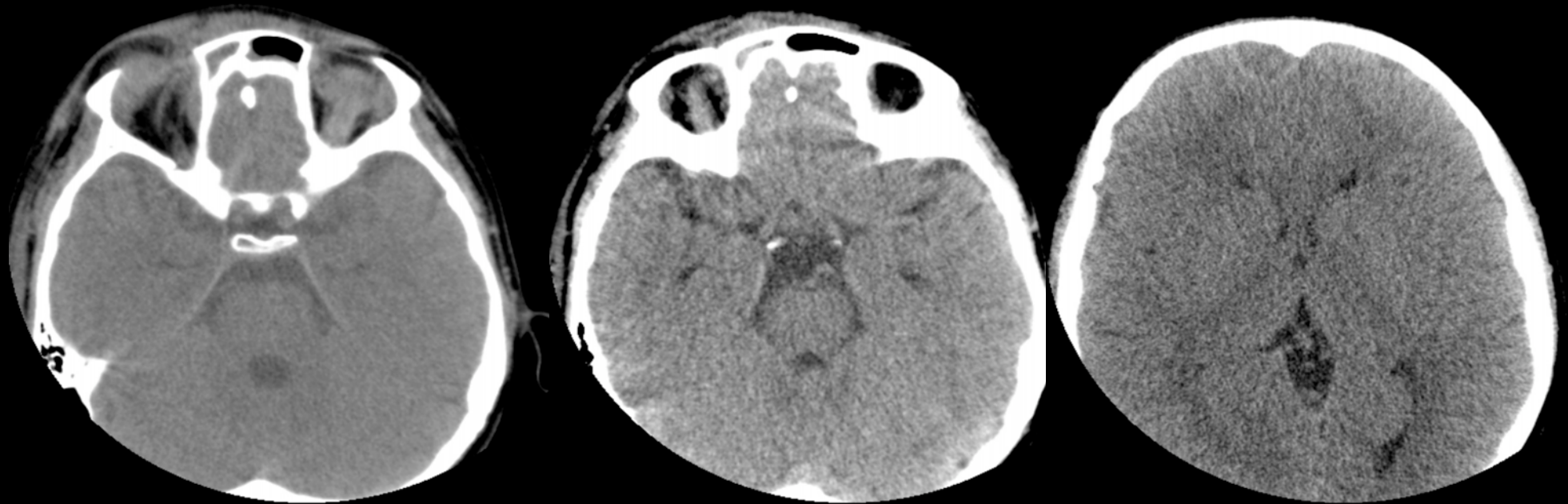
頭蓋骨 Waters 像



副鼻腔横断像 CT (1) (下→上)



副鼻腔横断像 CT (2) (下→上)



副鼻腔冠状断像 CT

