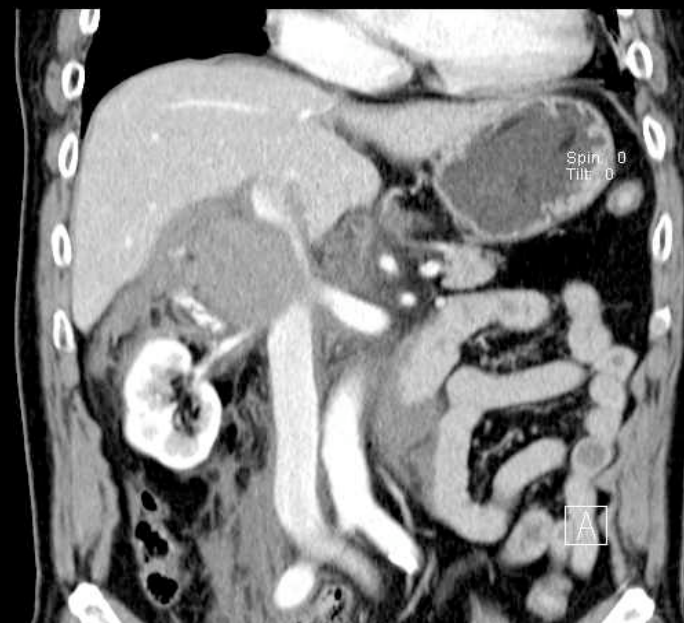
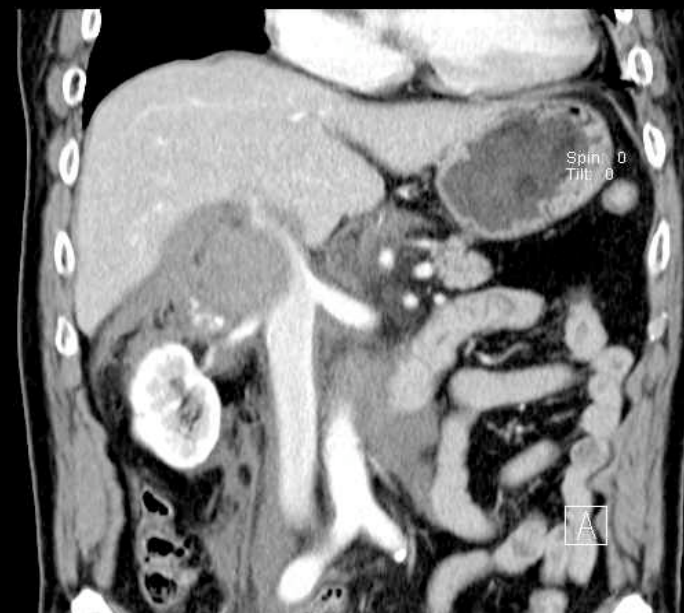
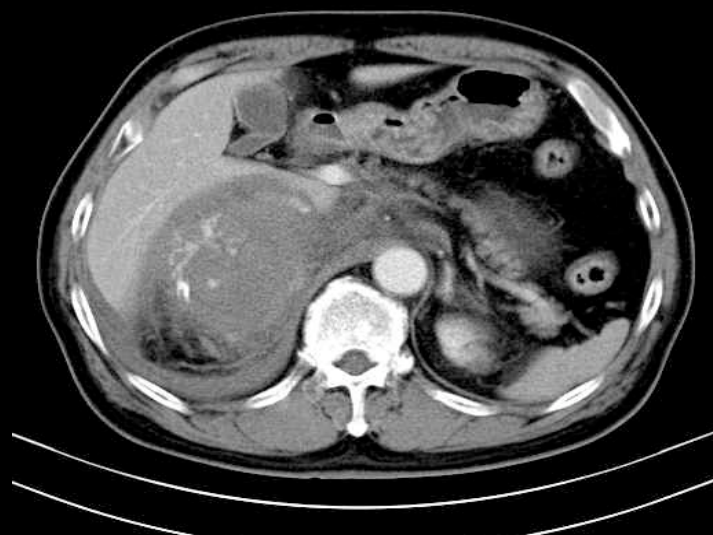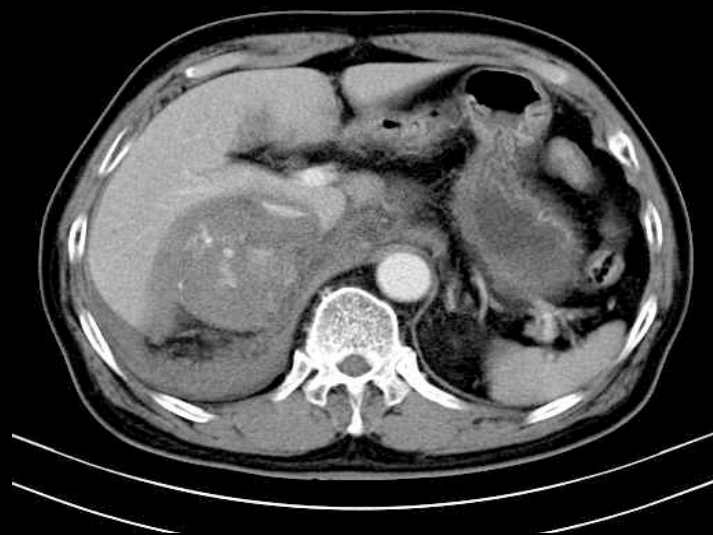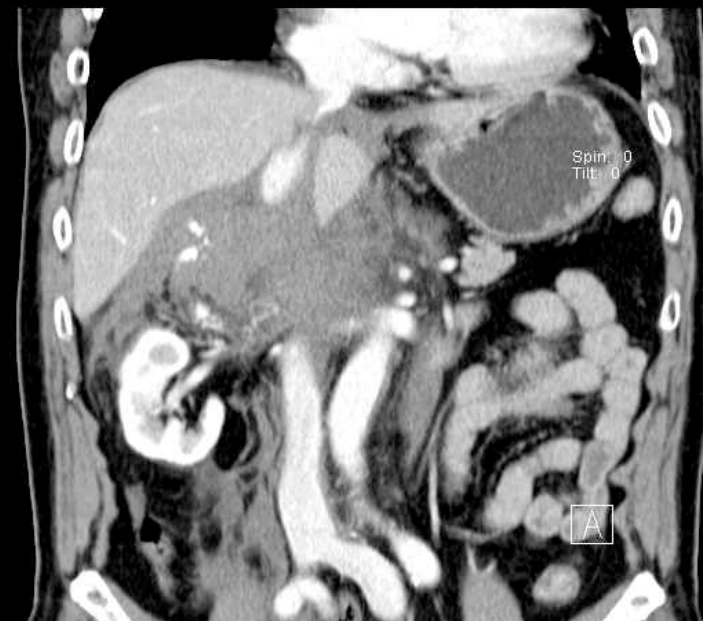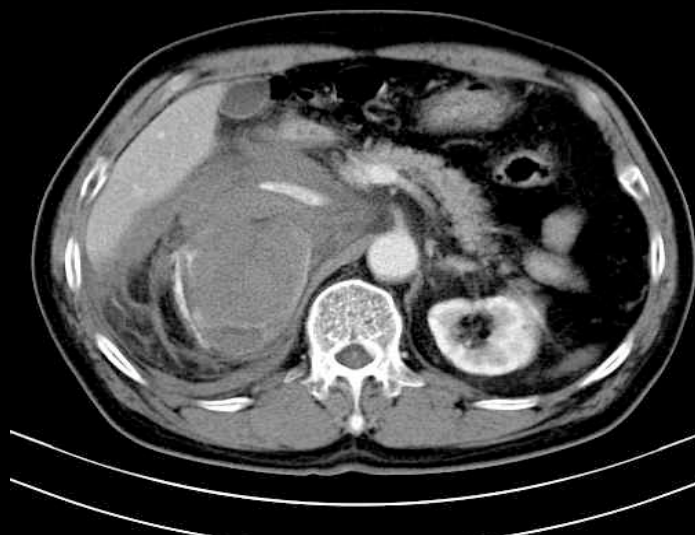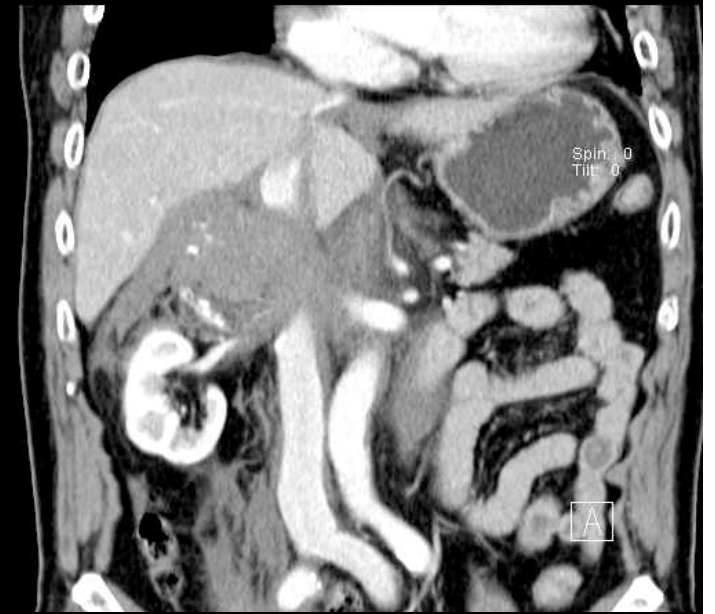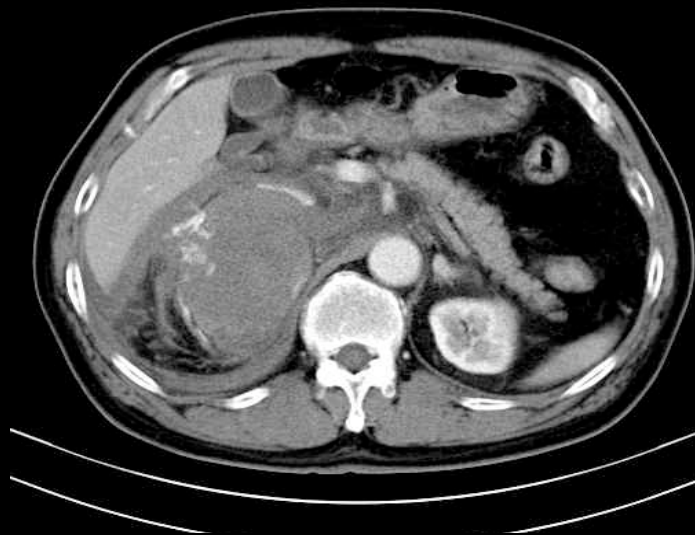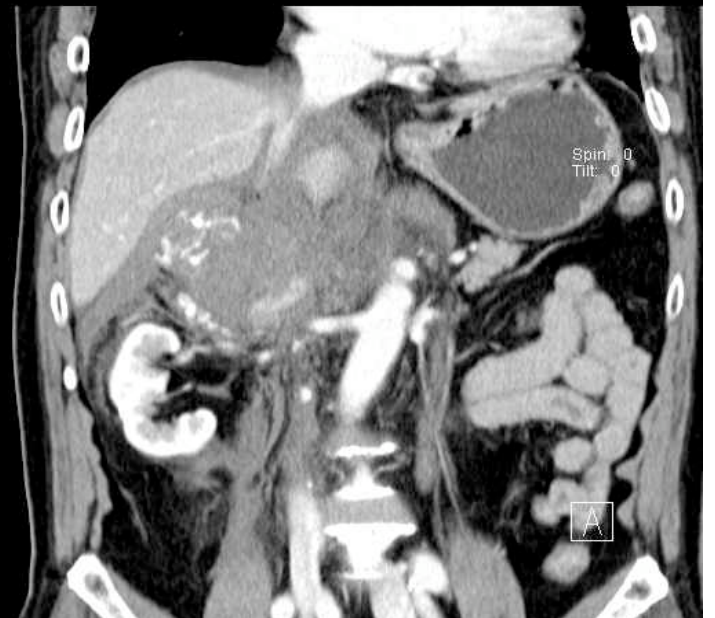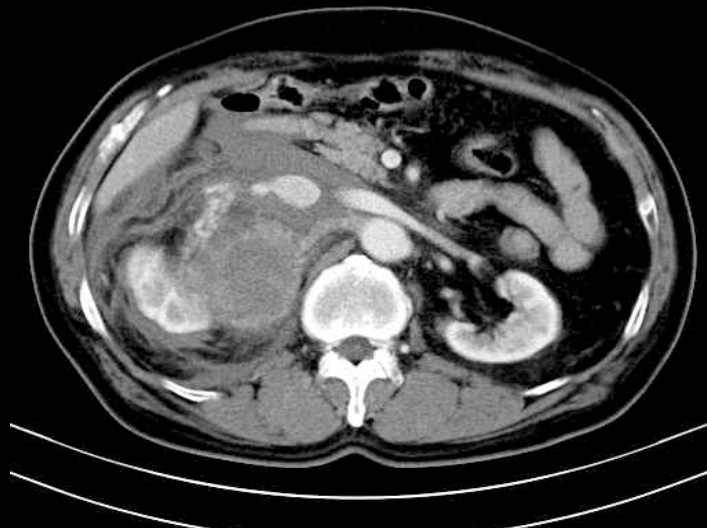
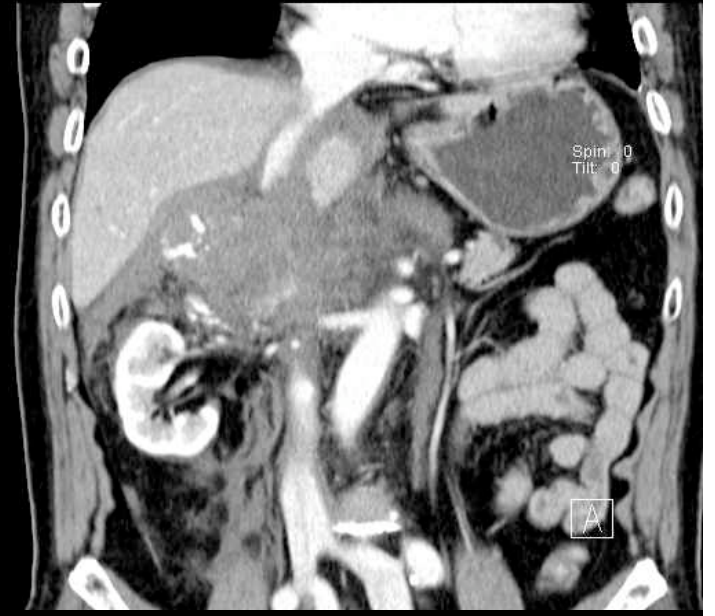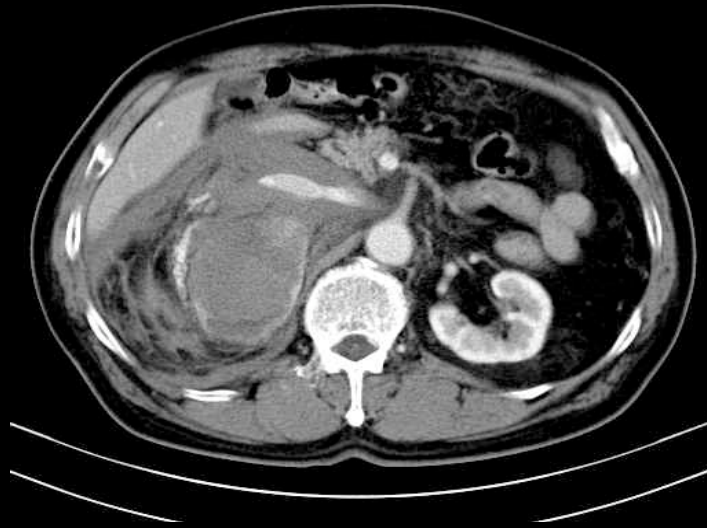入院時

造影 CT axial 像

coronal 像

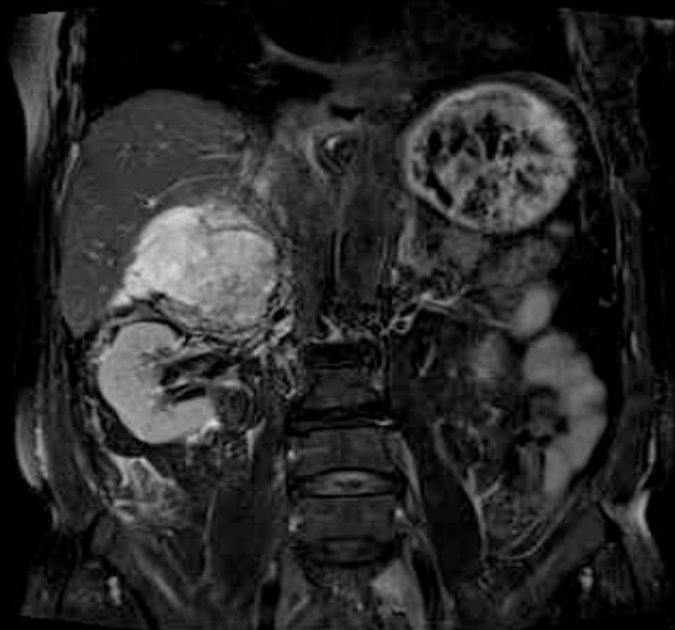






# 入院10日目

FS T2 coronal



CE FS T1 axial

