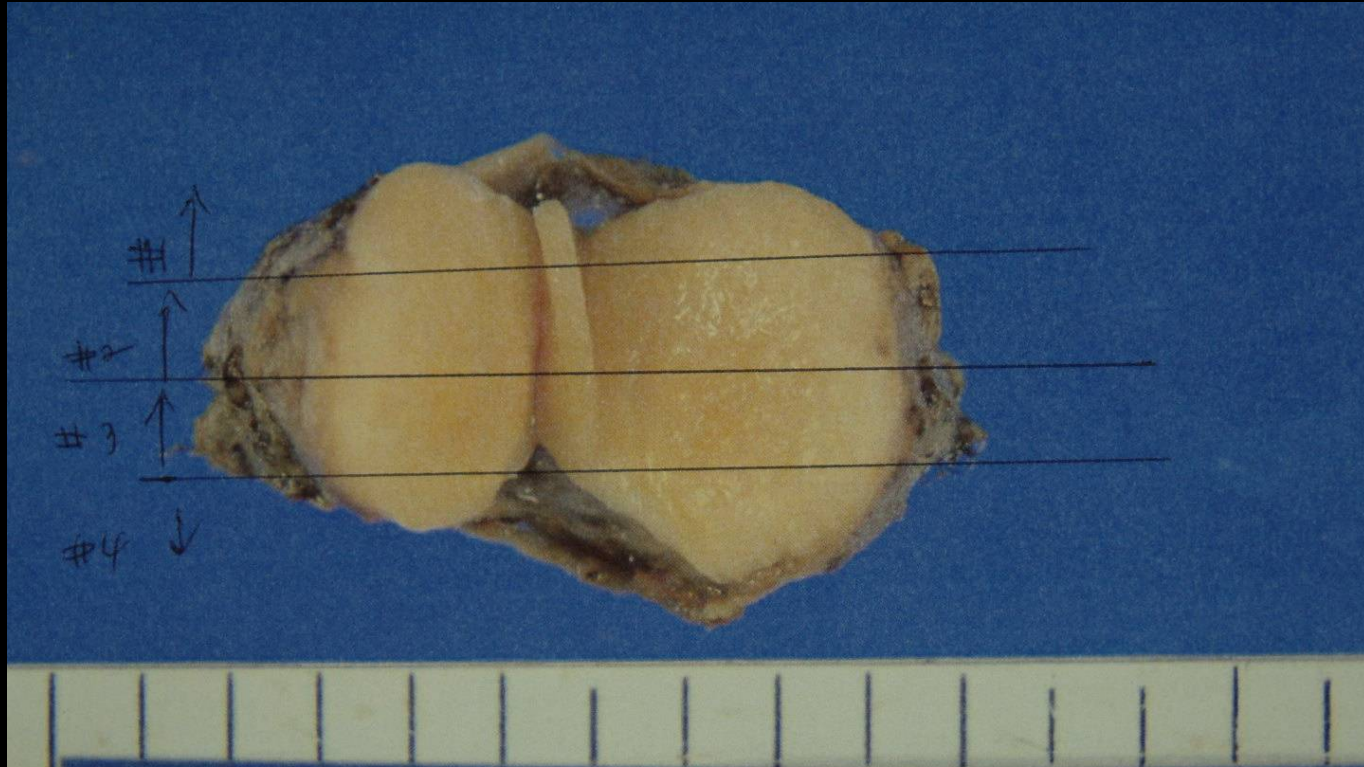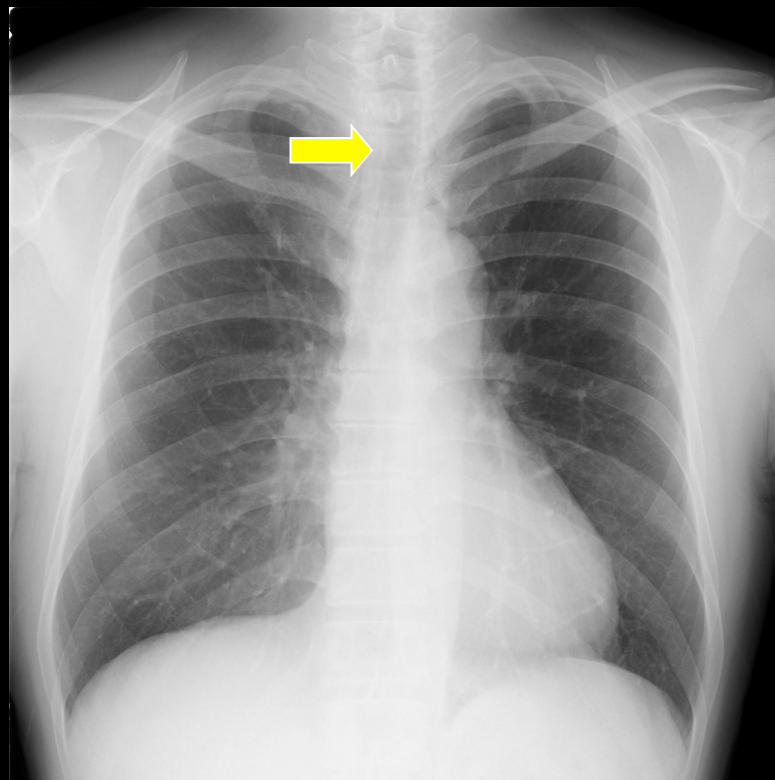


均一な淡黄色腫瘍

# 胸部単純写真



気管の軽度圧排