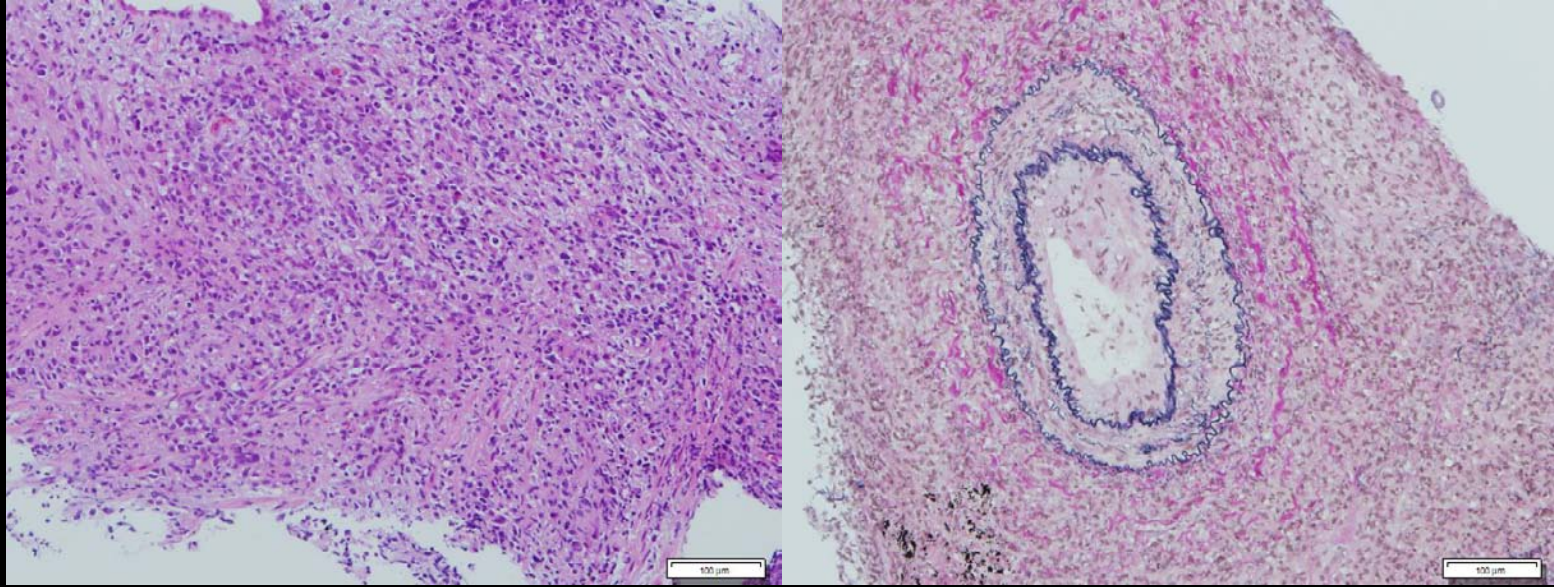
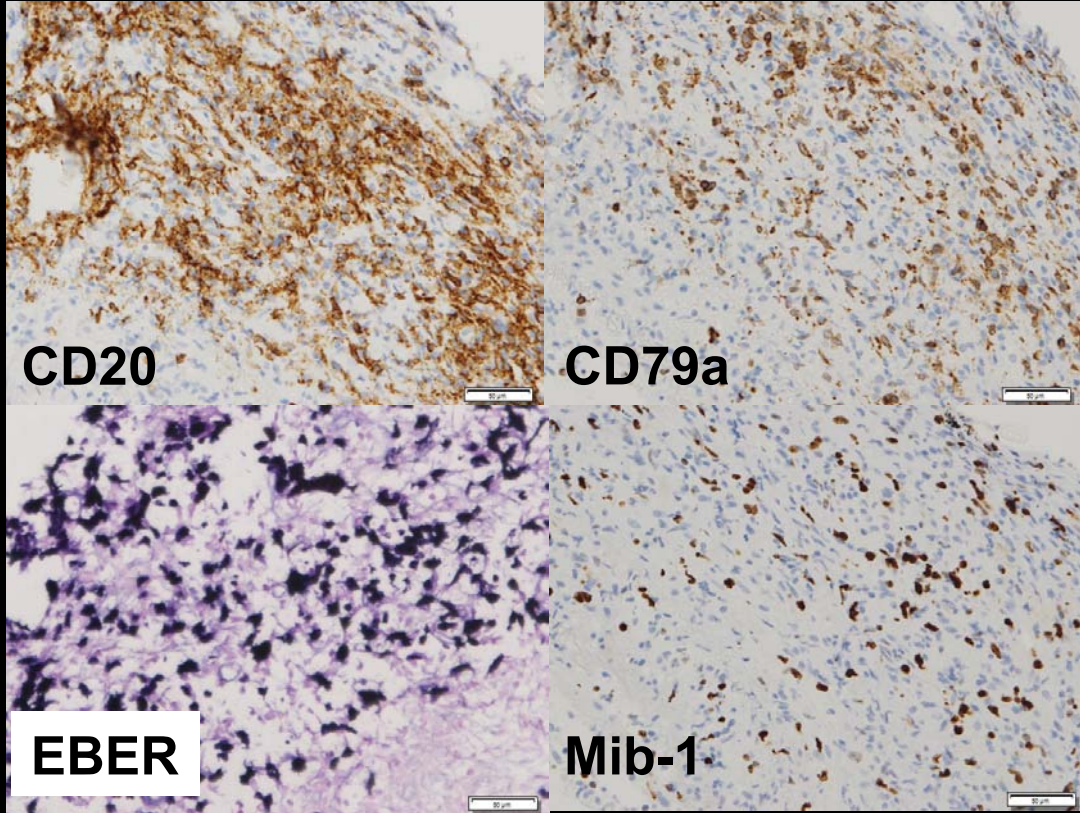


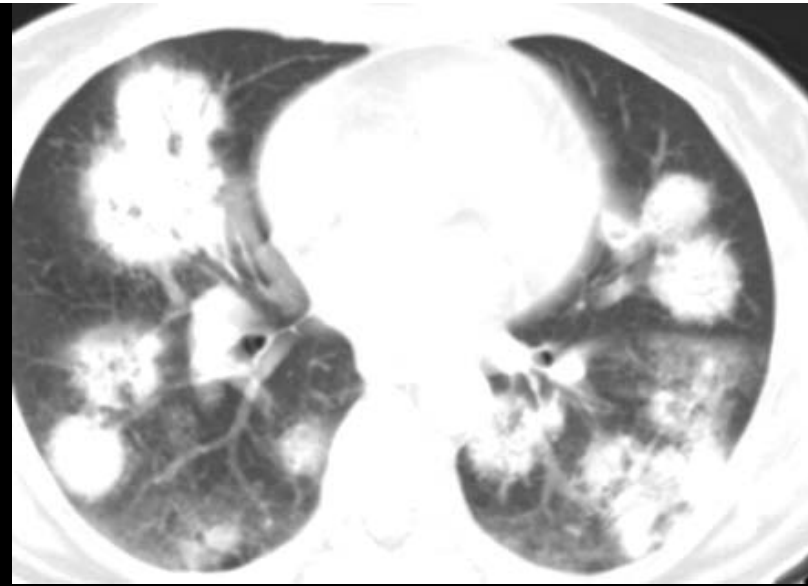
病理所見 (TBLB)



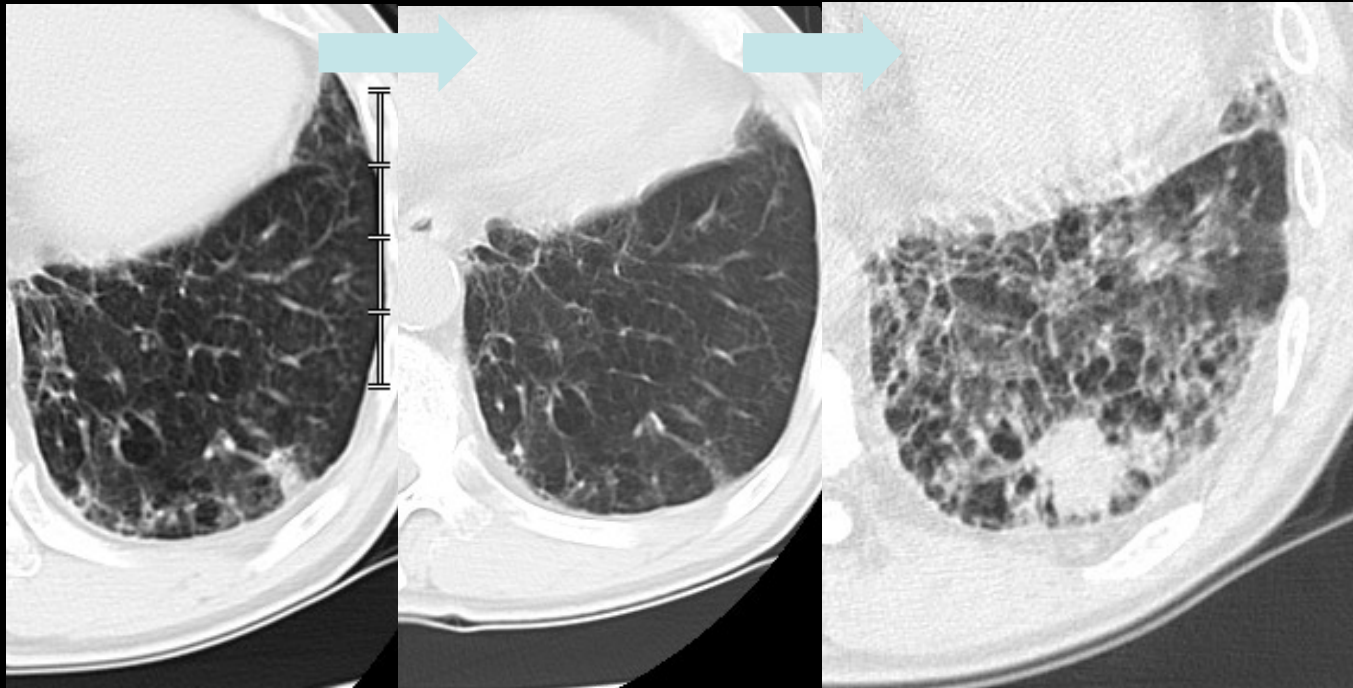
HE染色

EVG染色





左下葉病変の比較

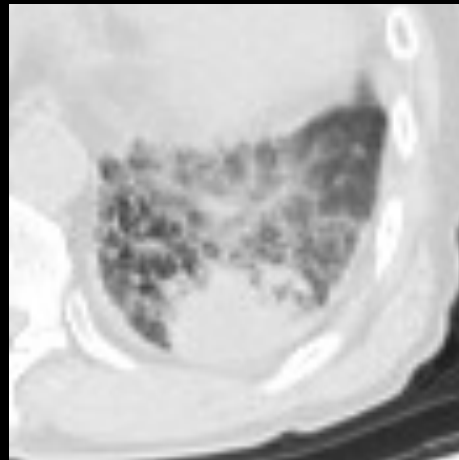


4年半前

2年半前

3日後

2ヶ月後PET-CT



3ヶ月後CT

