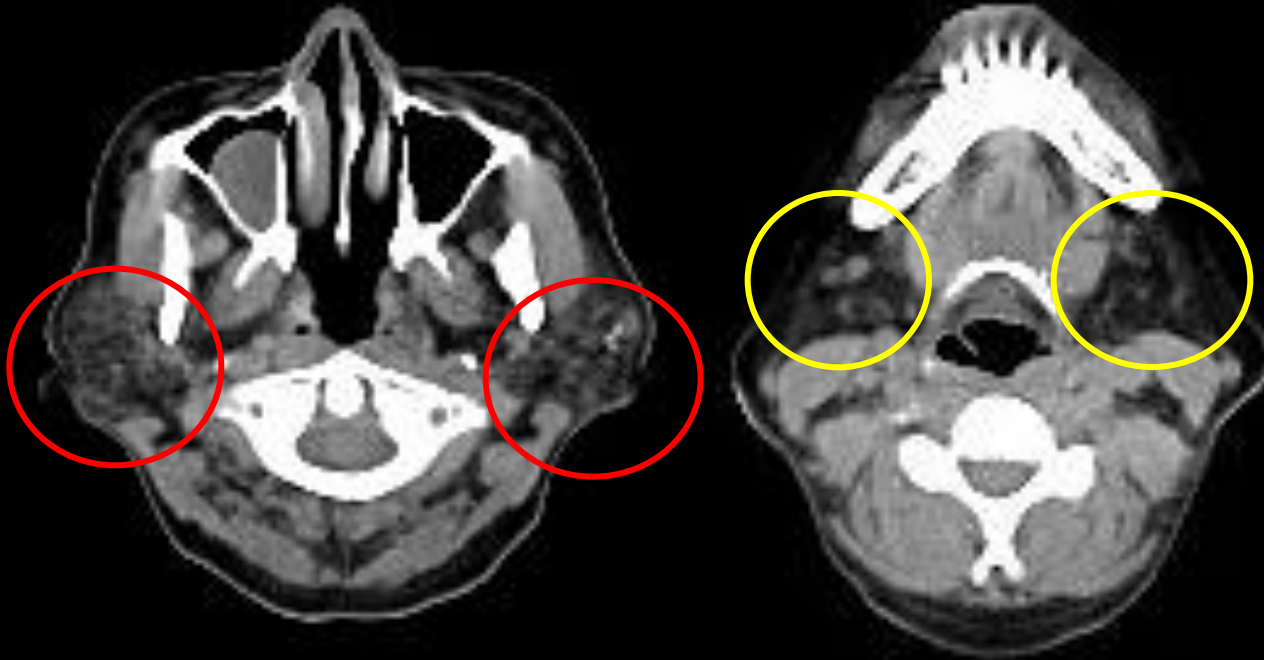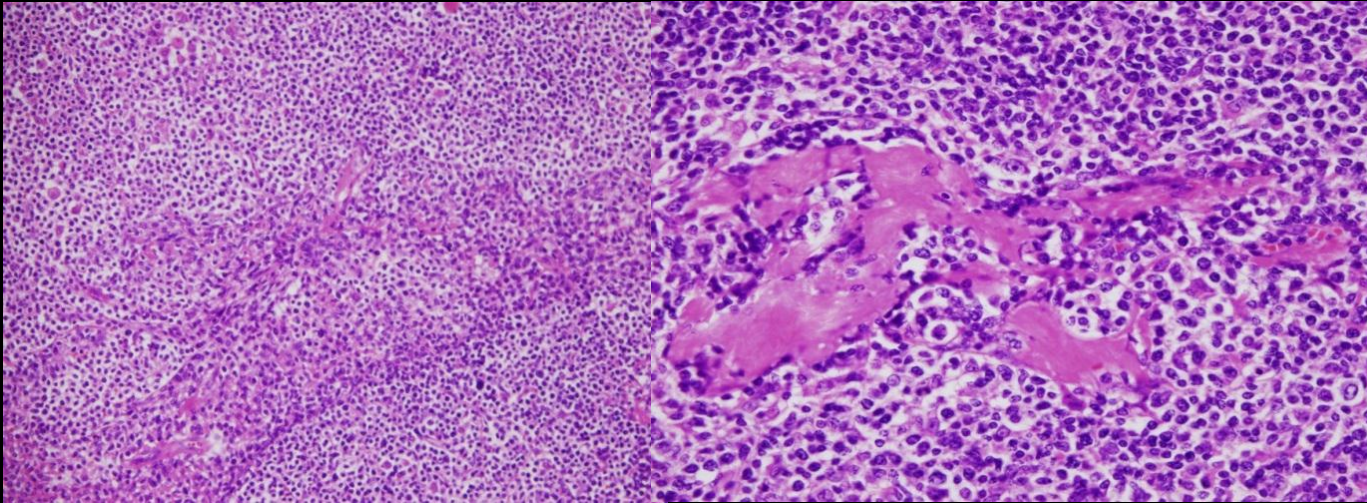


# PET-CT

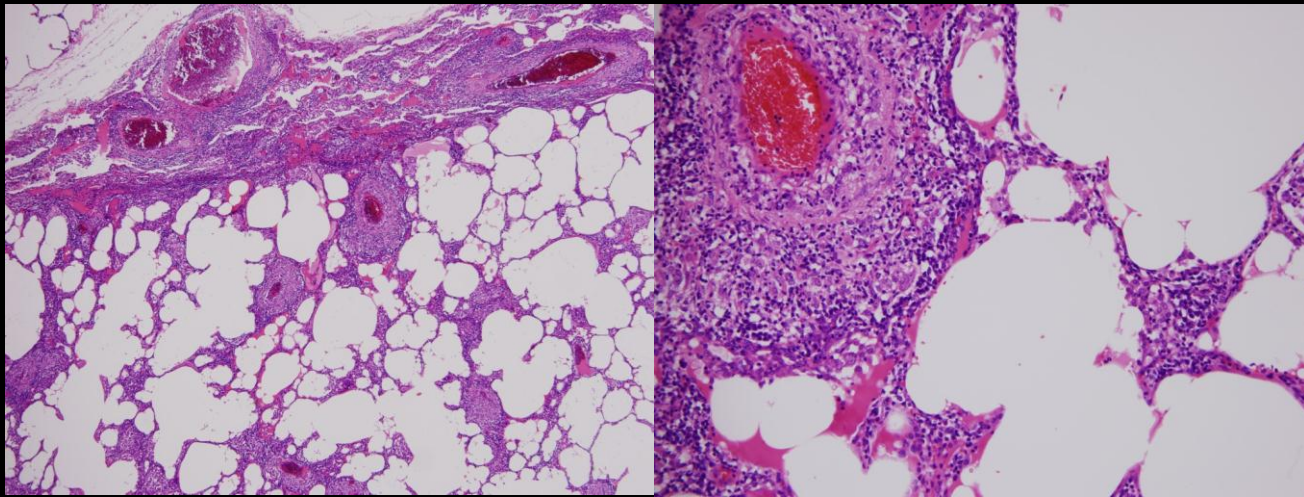


# 病理所見：前縱隔腫瘤



MALToma ; mucosa-associated lymphoid tissue lymphoma

# 病理所見：肺組織



DLH ; diffuse lymphoid hyperplasia  
(LIP; Lymphocytic interstitial pneumonitis)