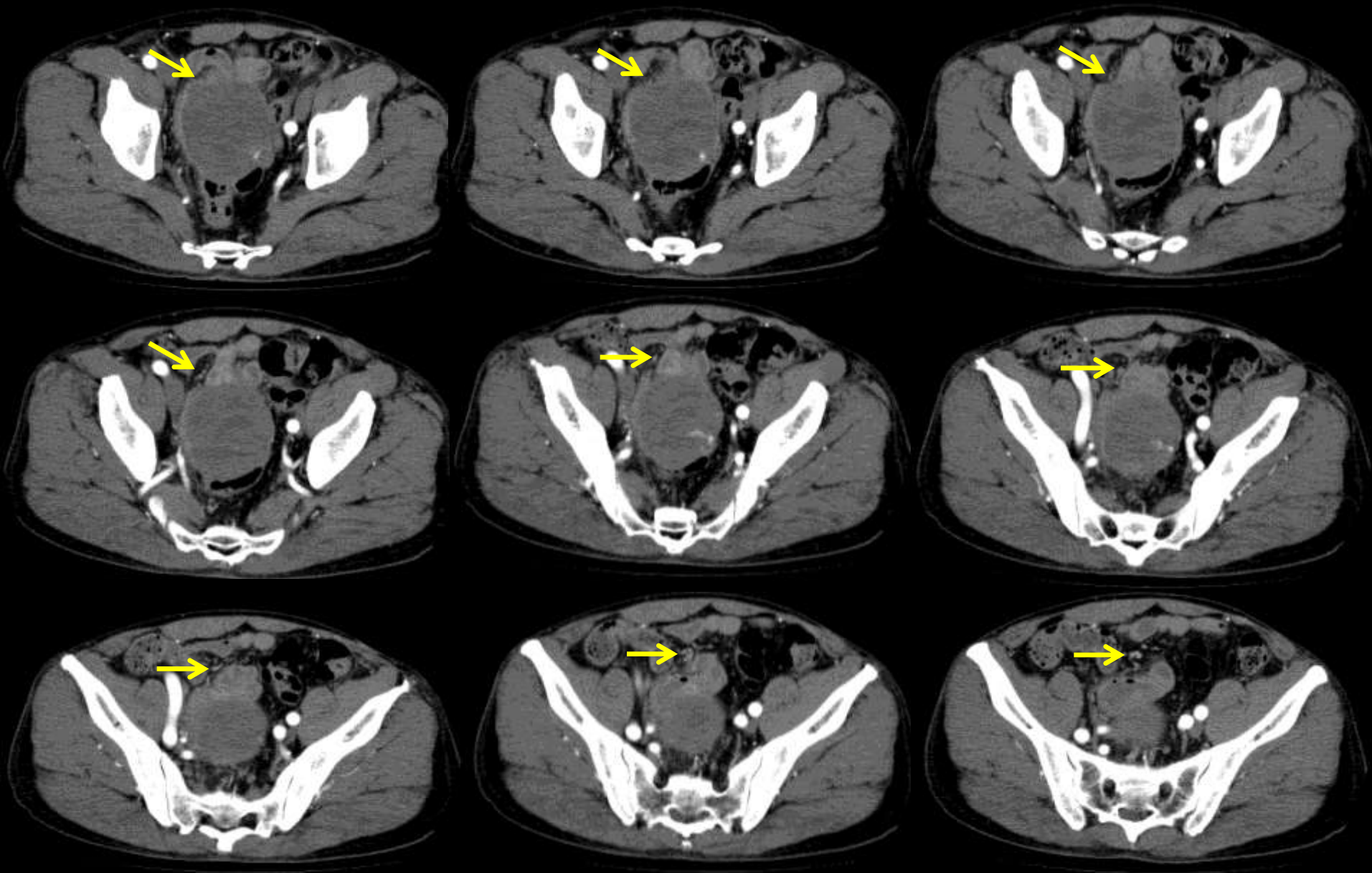
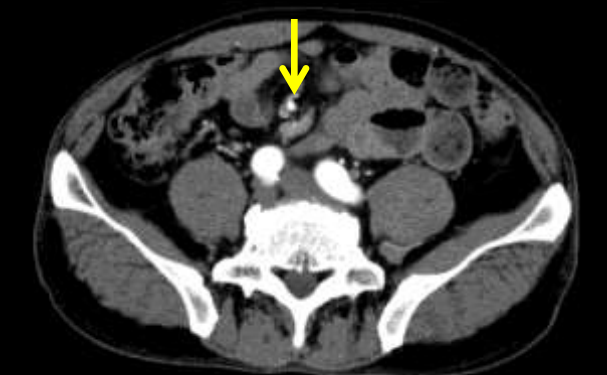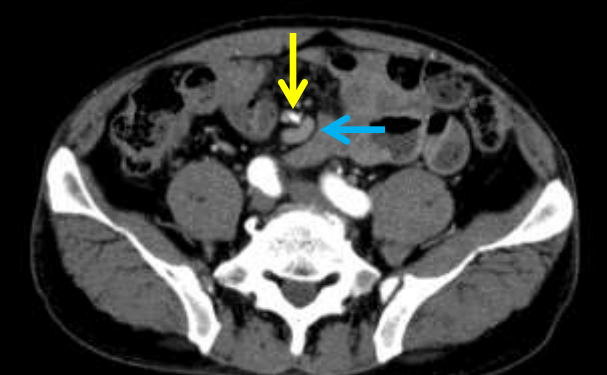
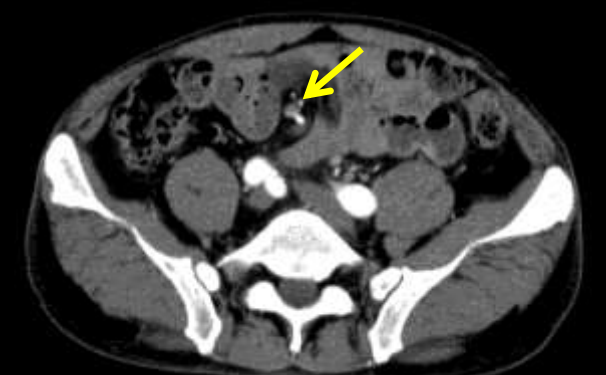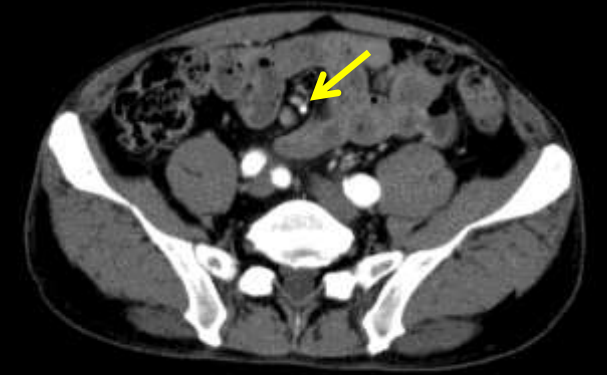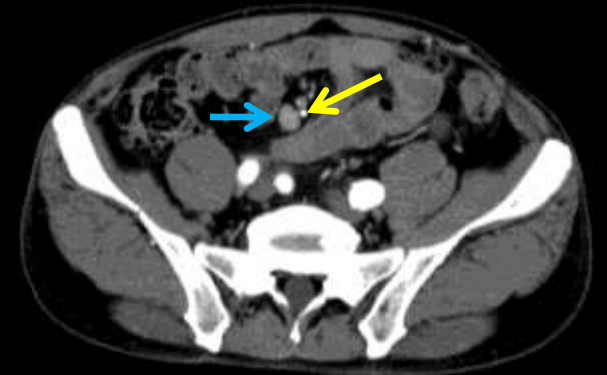
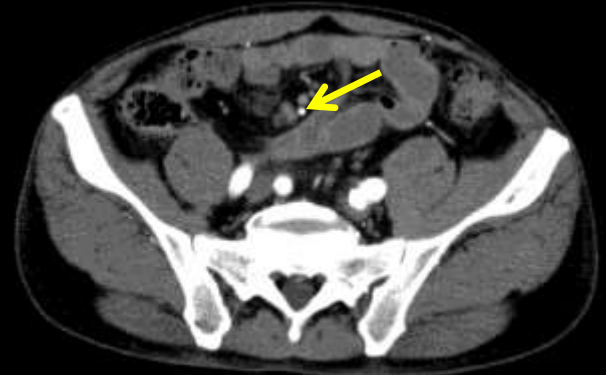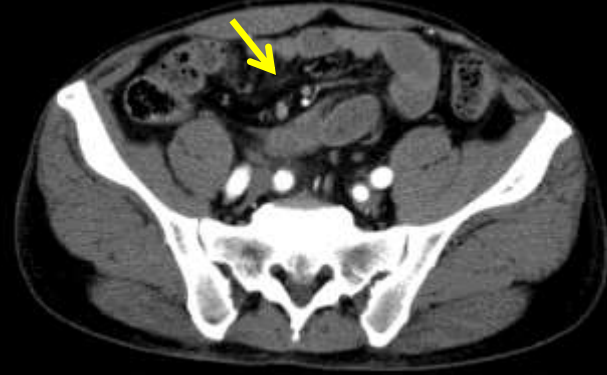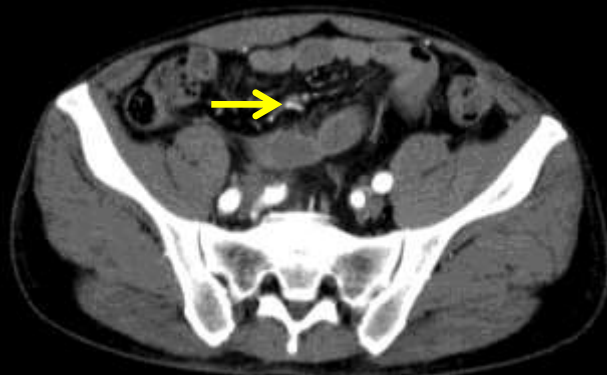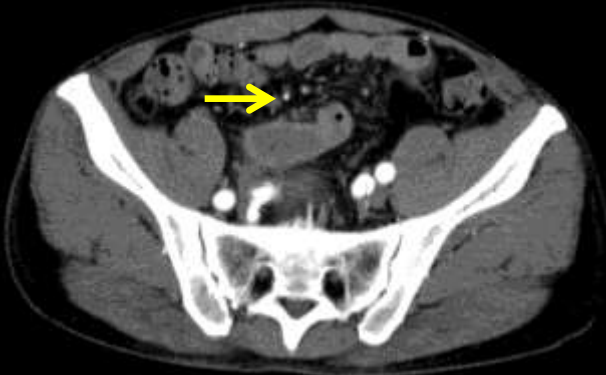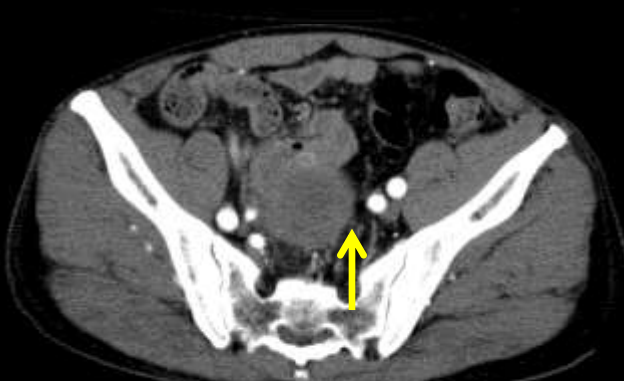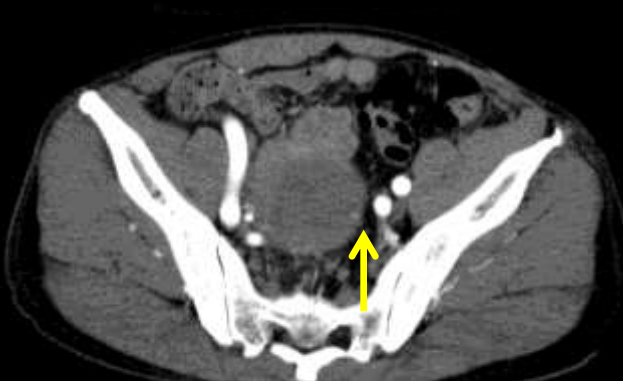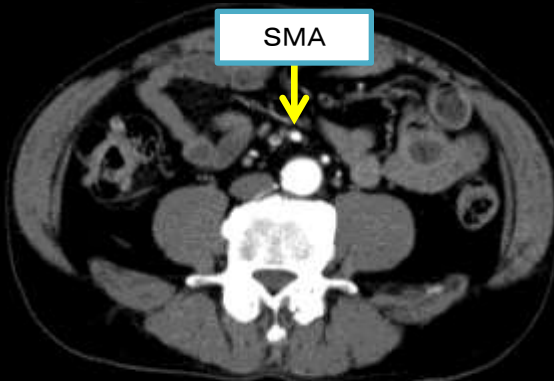
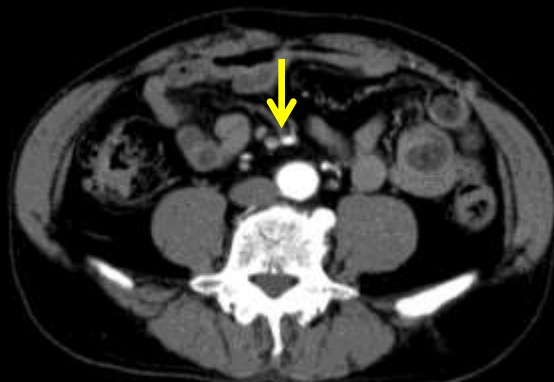
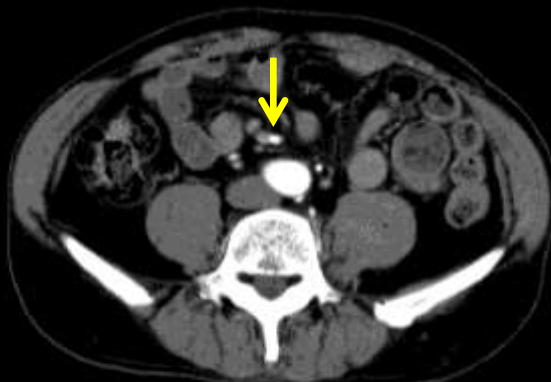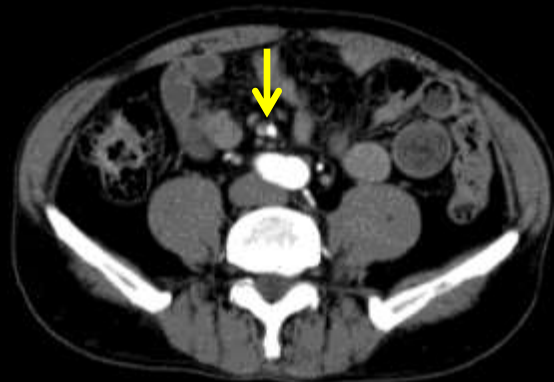
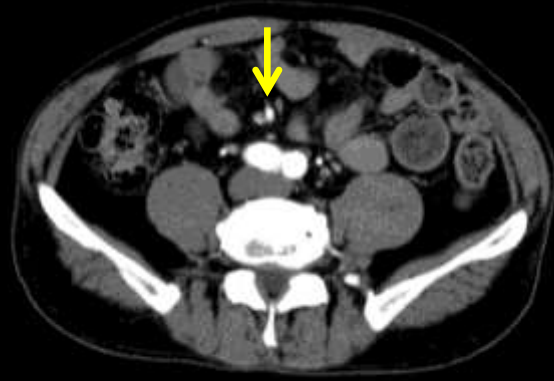
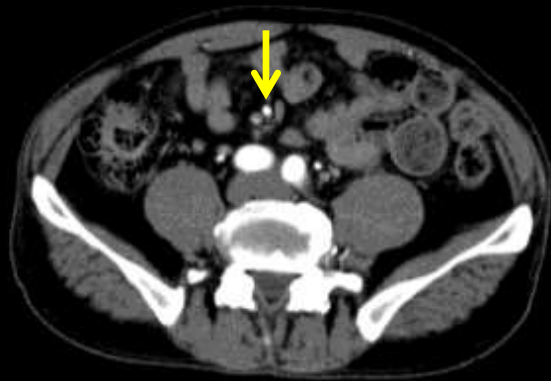
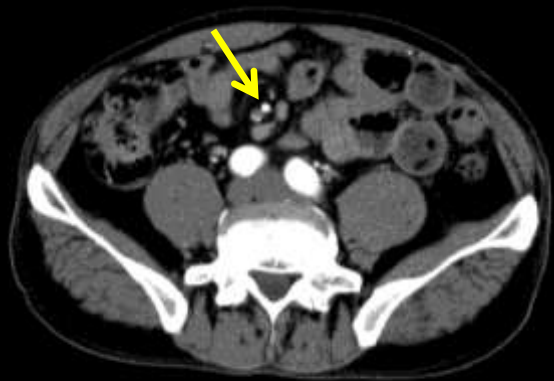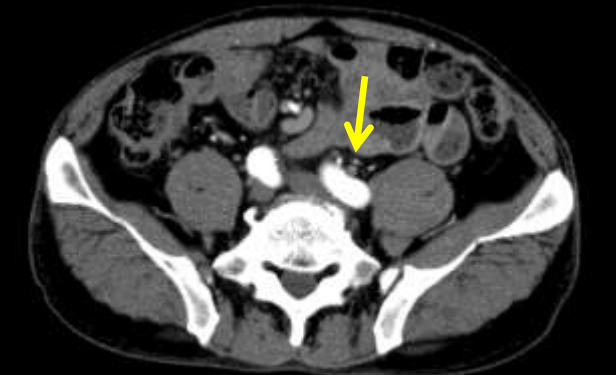
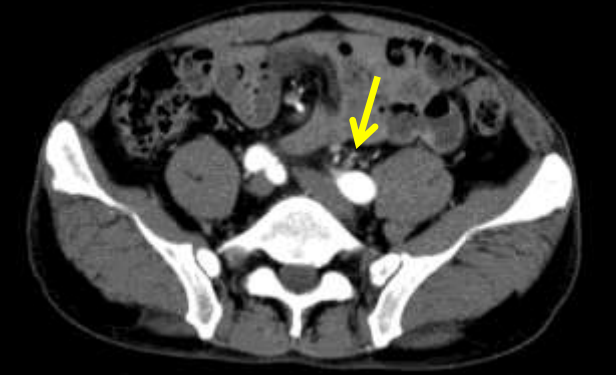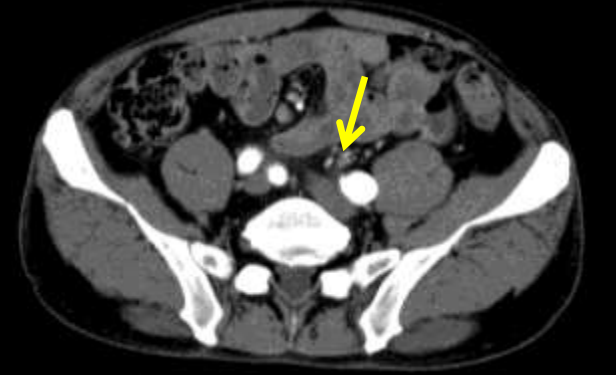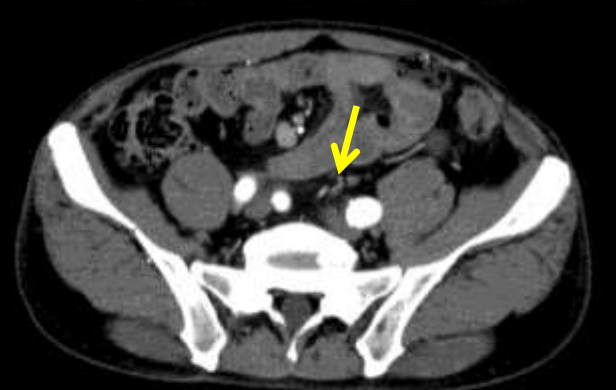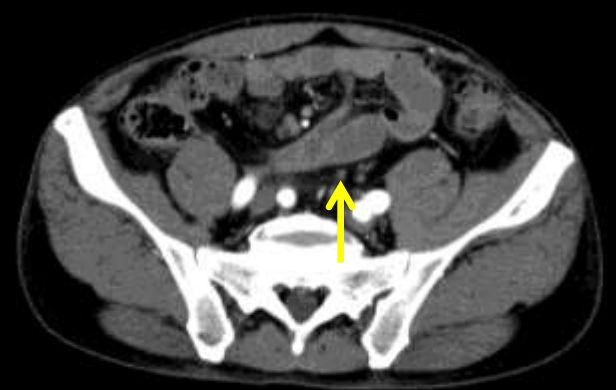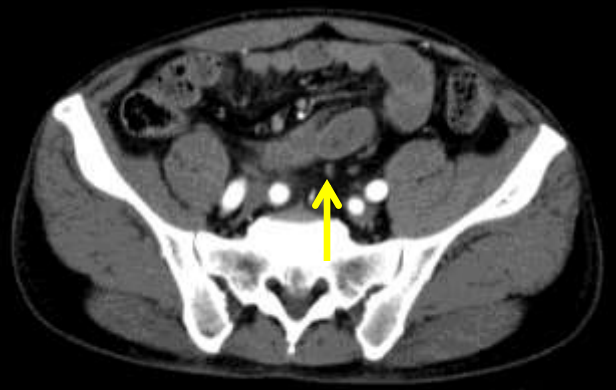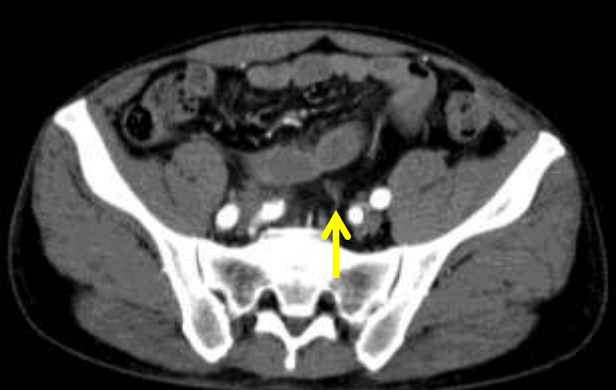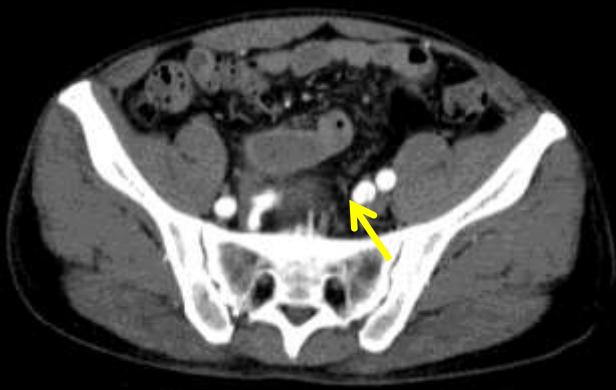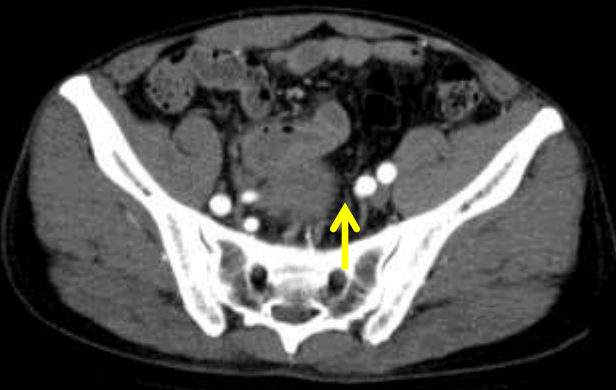


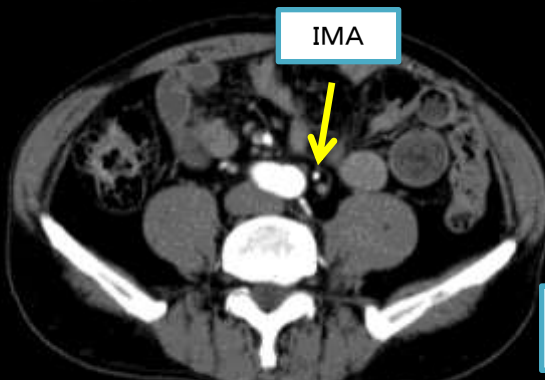
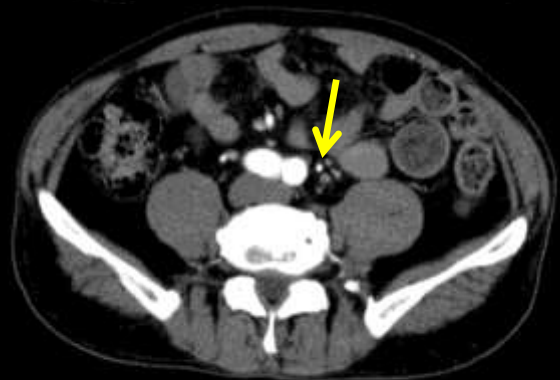
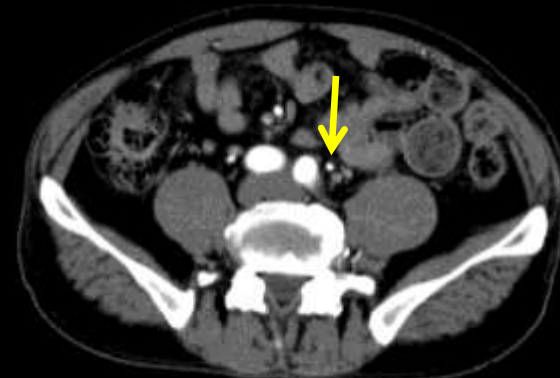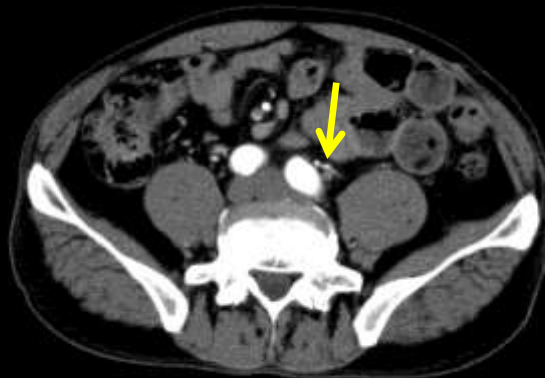
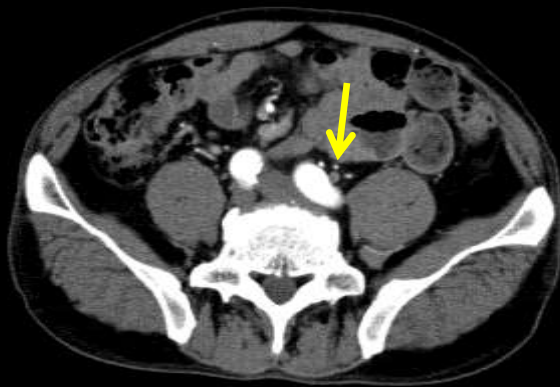
# 造影CT











SMA、IMAからの血流支配？  
→腸管あるいは腸間膜由来？

