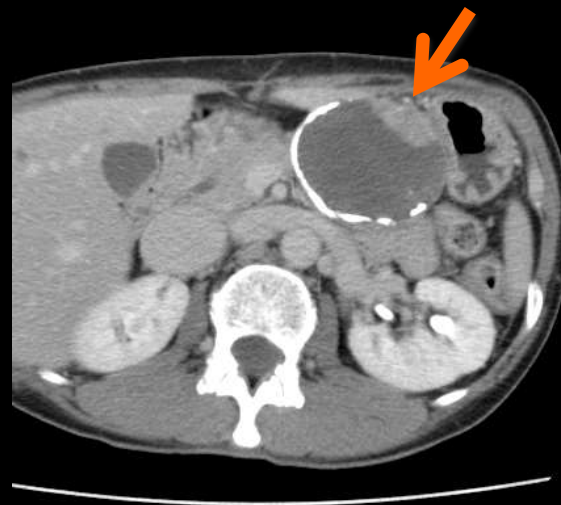
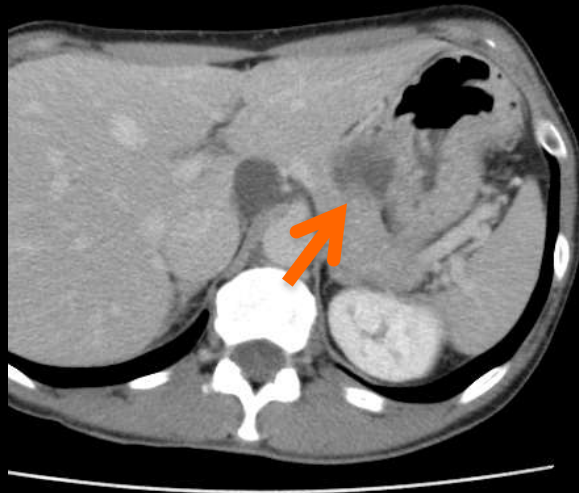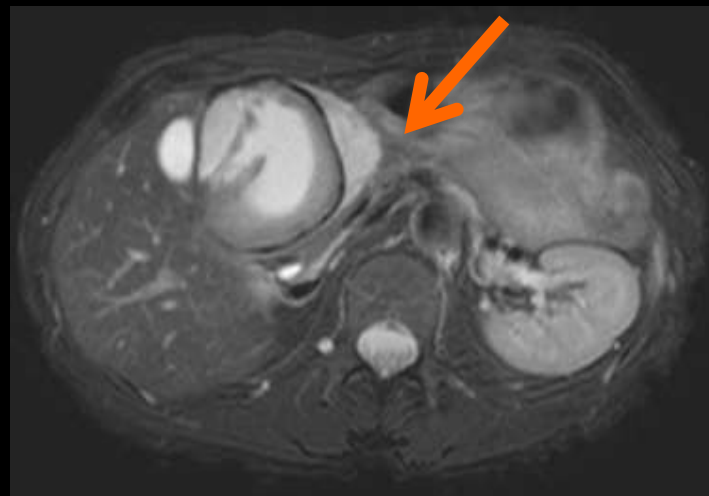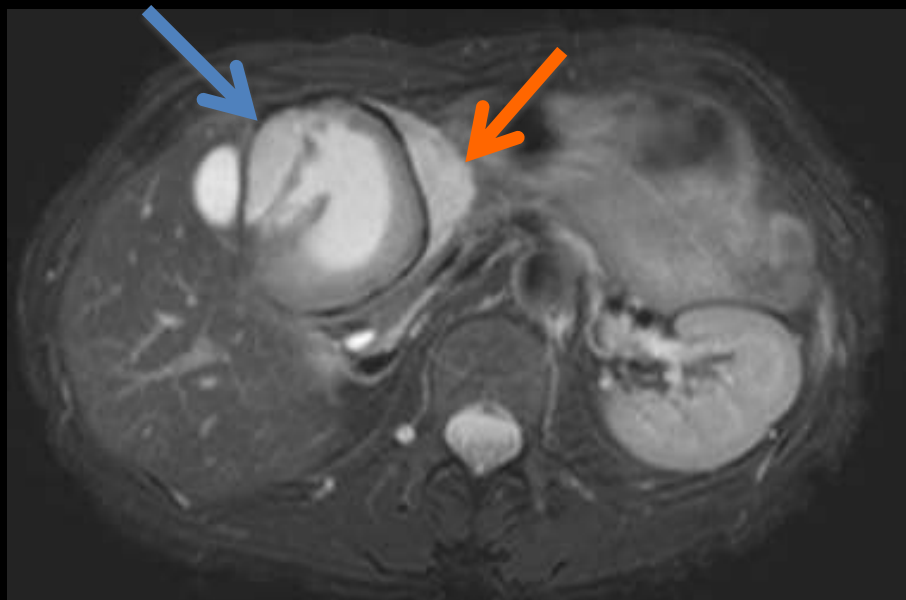
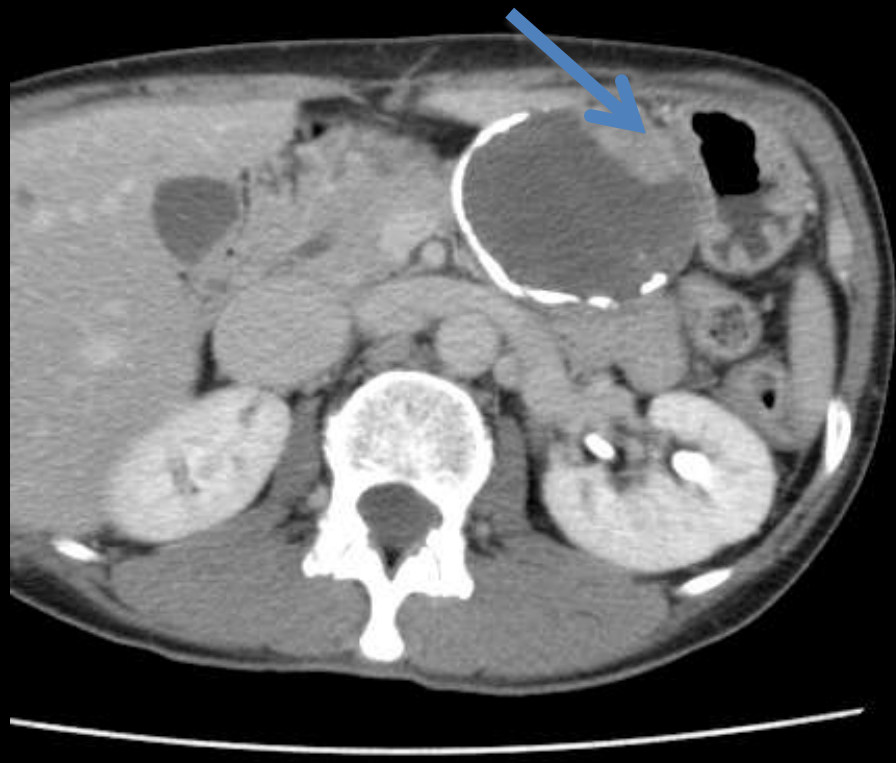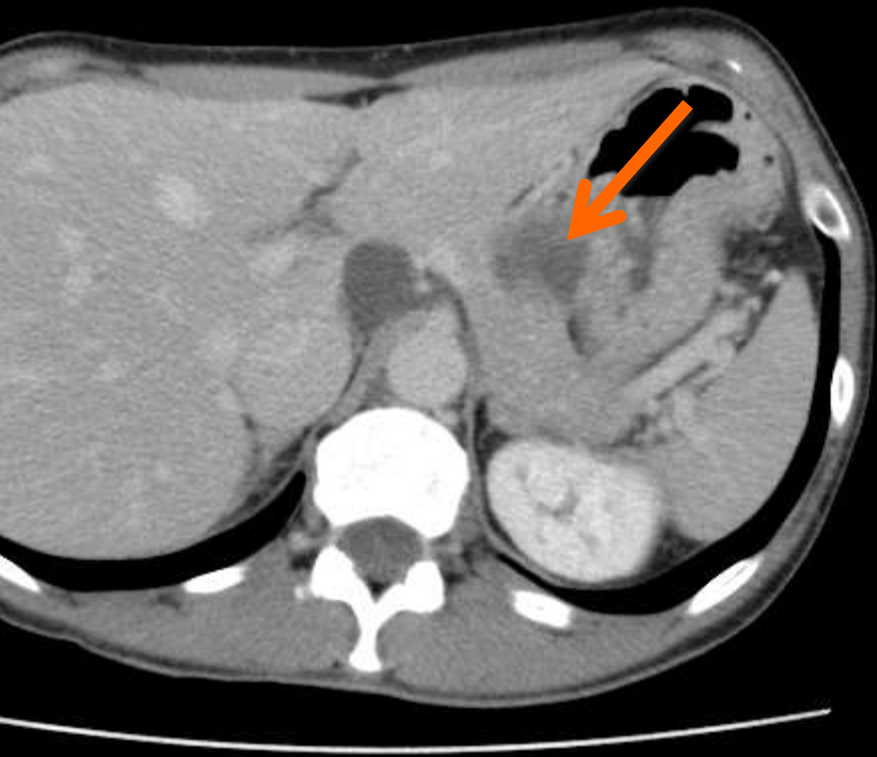


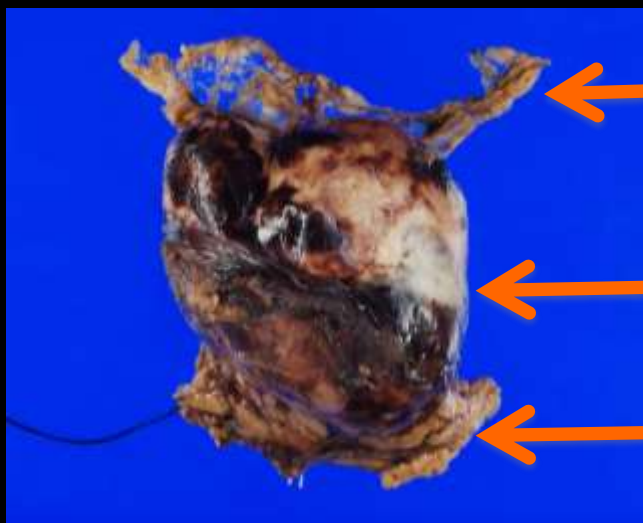造影CT



脂肪抑制T2WI
(CT施行9日後)







大網

腫瘍

臍体部



