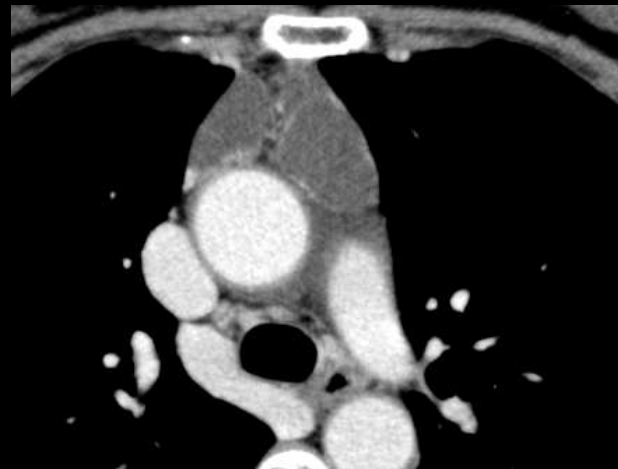
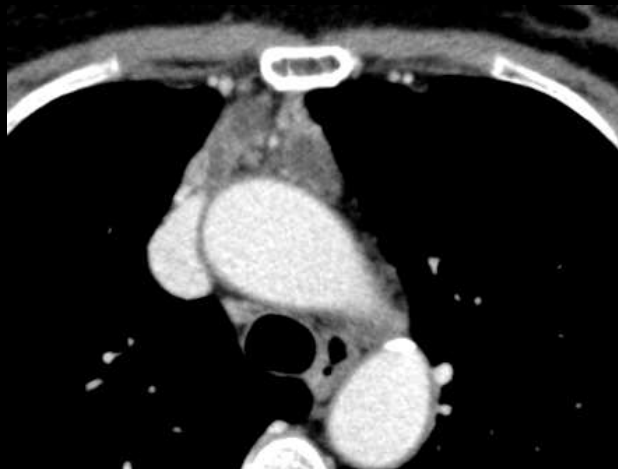
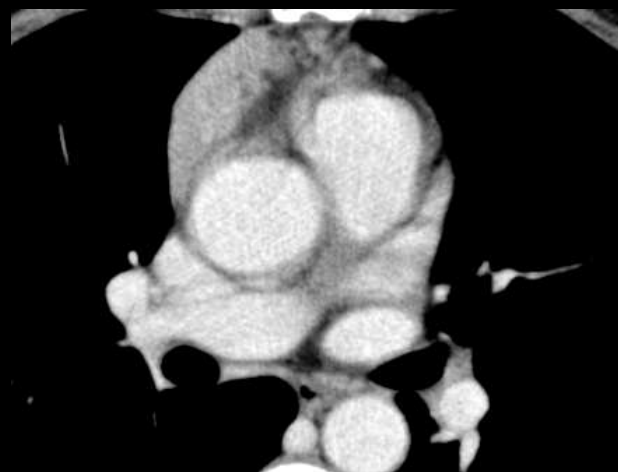
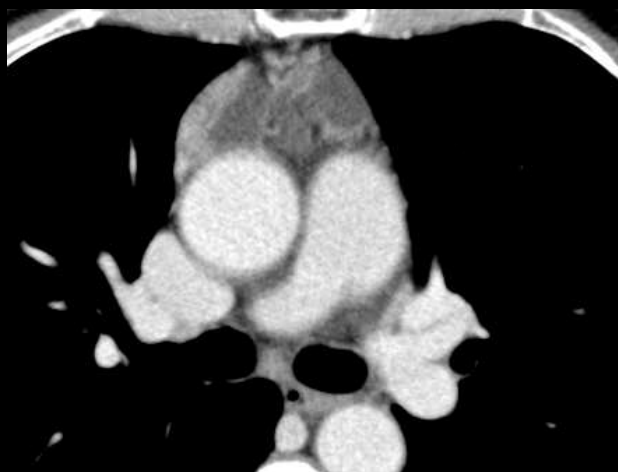
参考病例1：50代女性

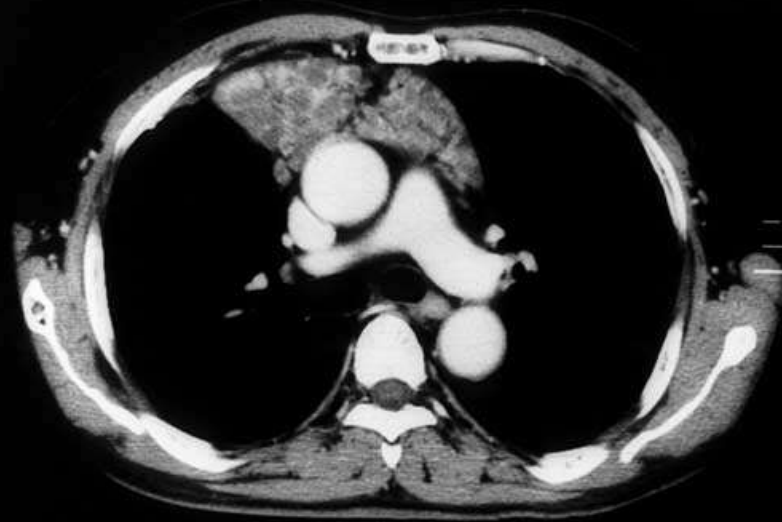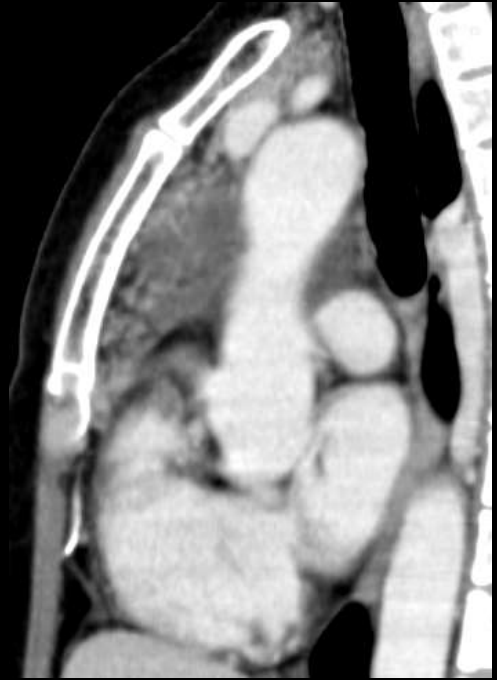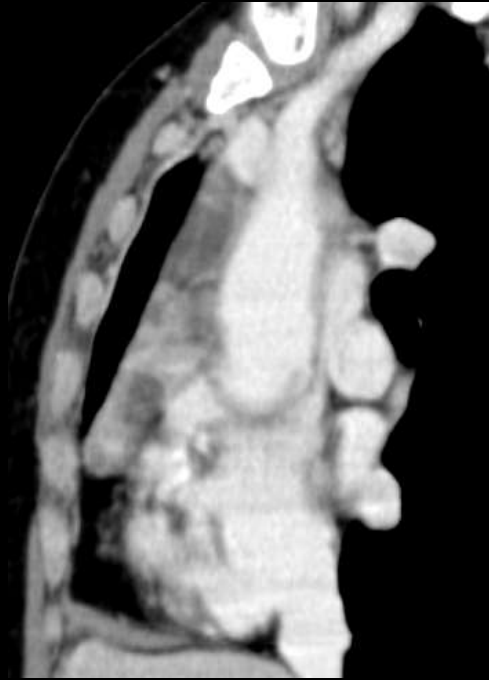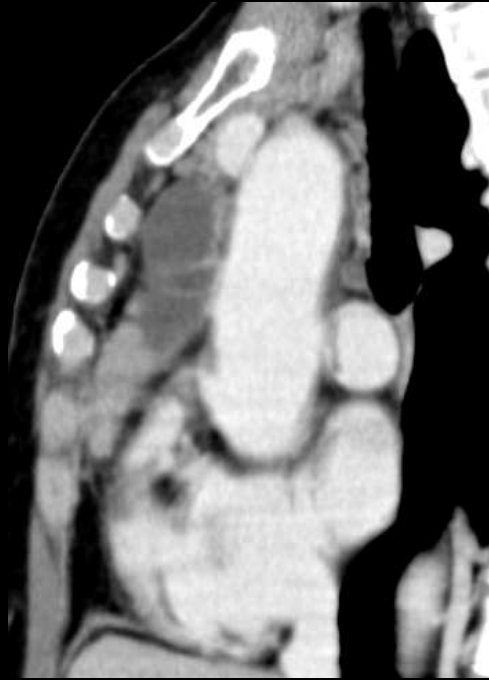
造影CT(軸位断)



造影CT(軸位断)

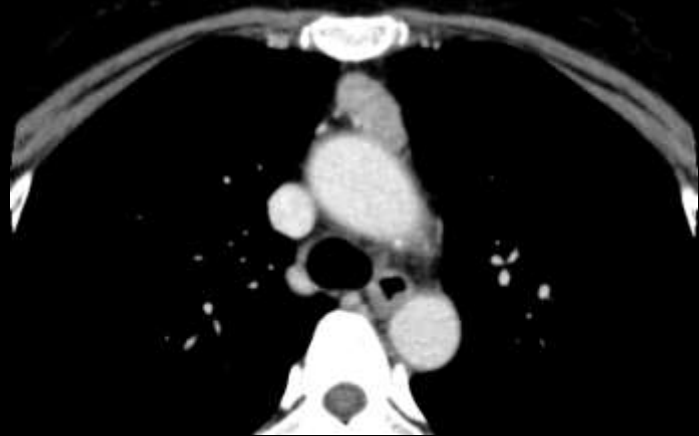
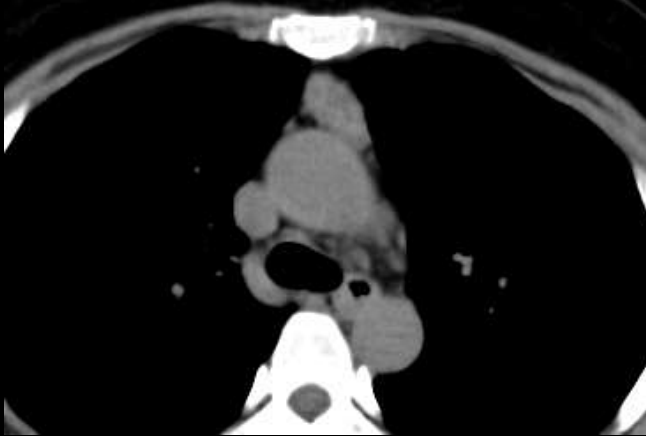

造影CT(矢状断)



参考症例2: 50代女性

单纯+造影CT(轴位断)



造影CT(轴位断)

