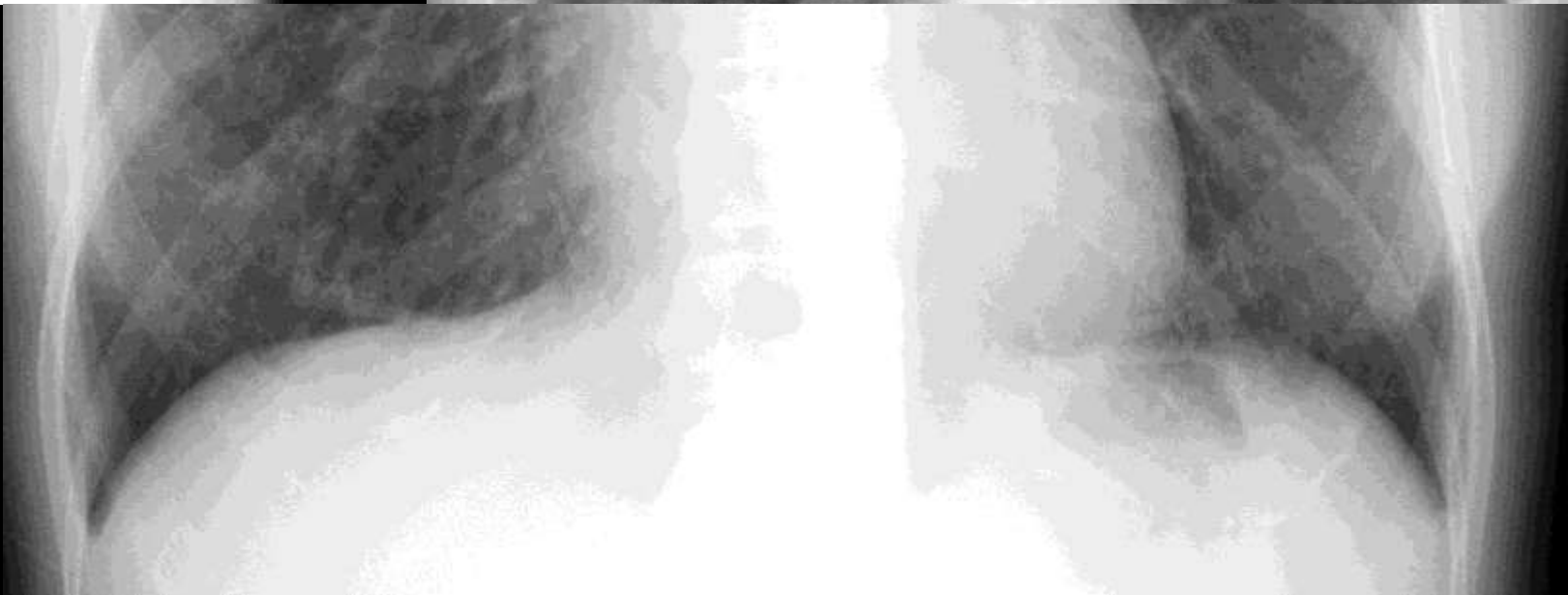
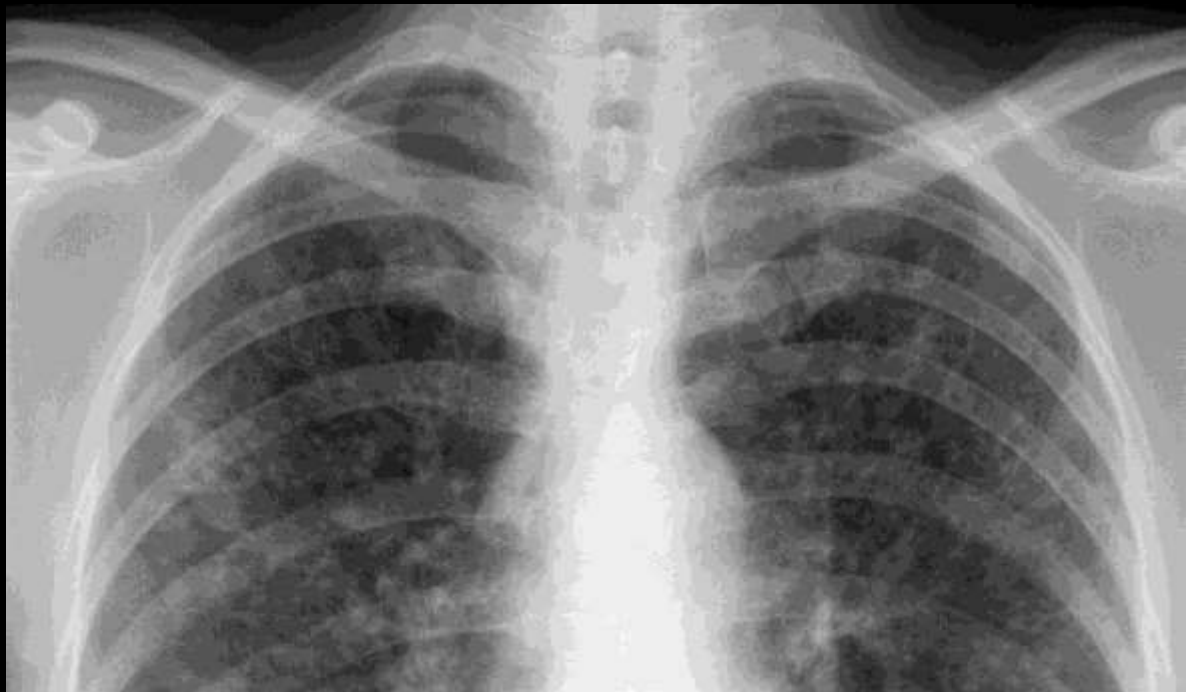
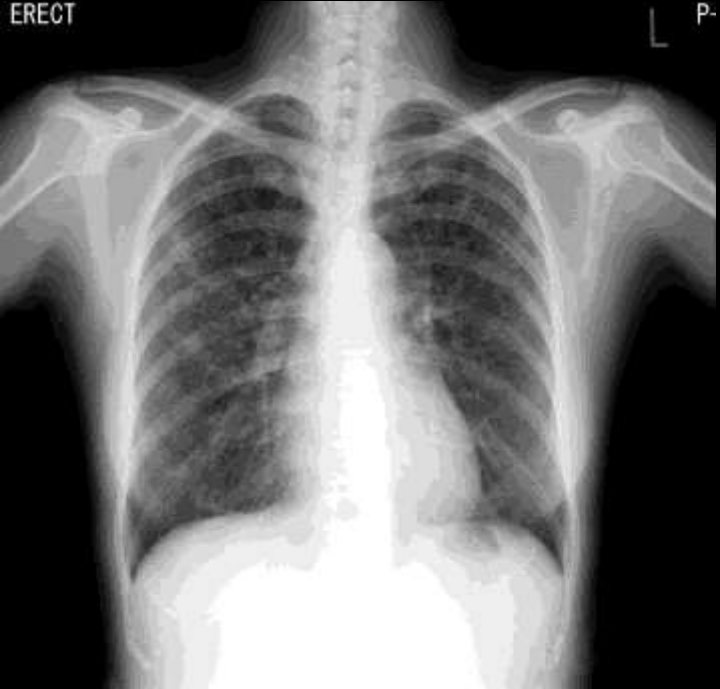
胸部単純X線写真

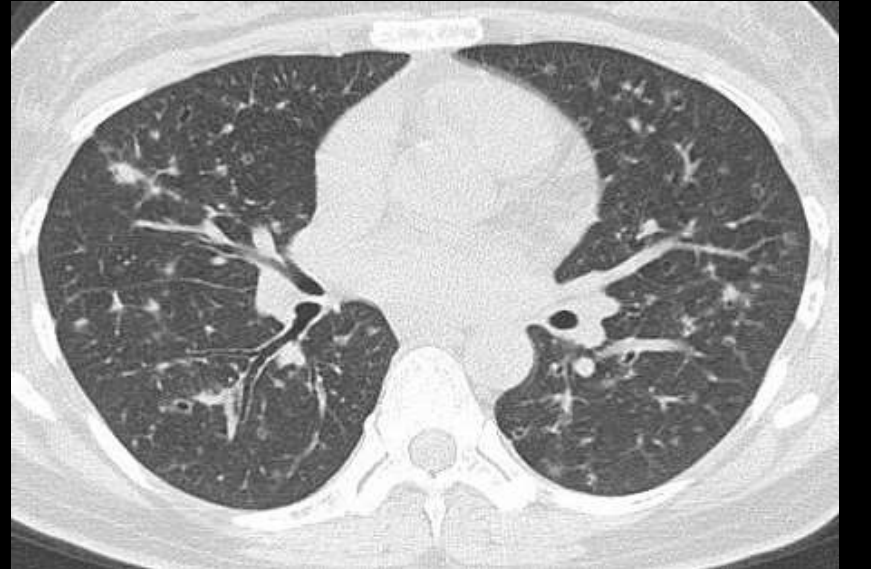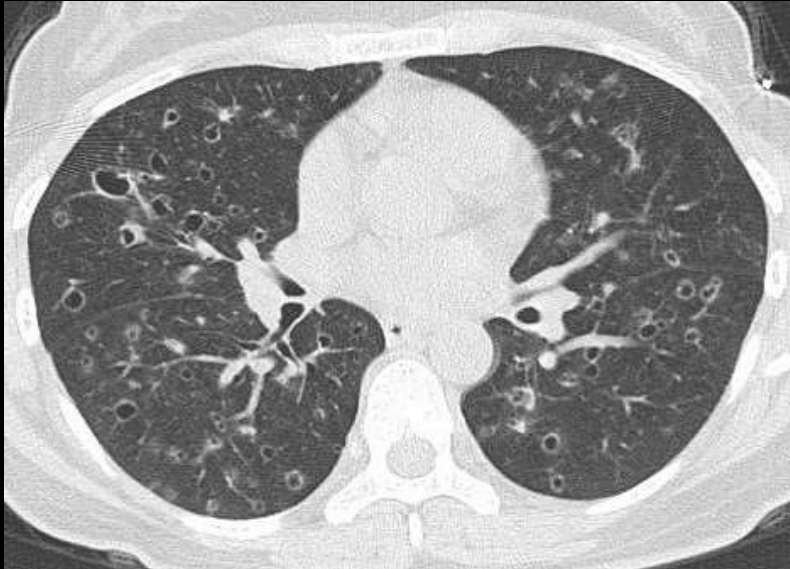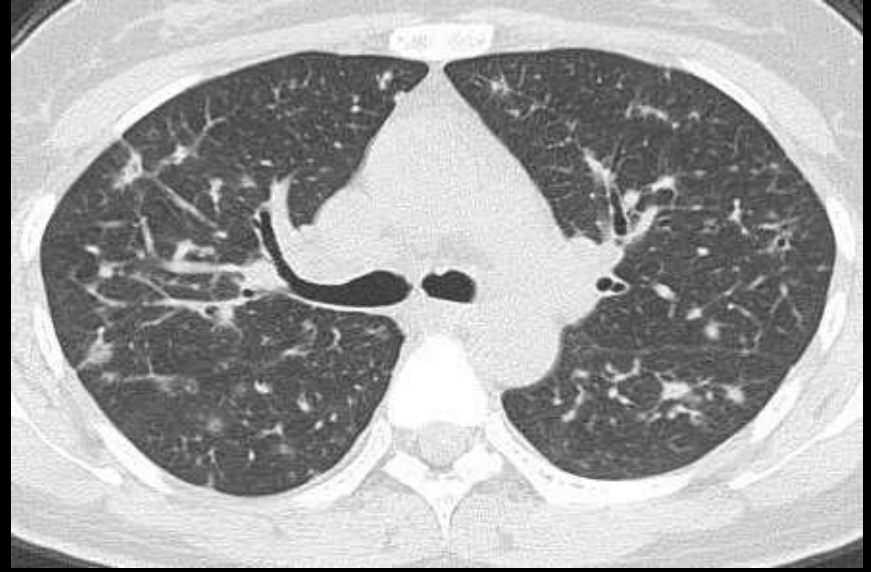
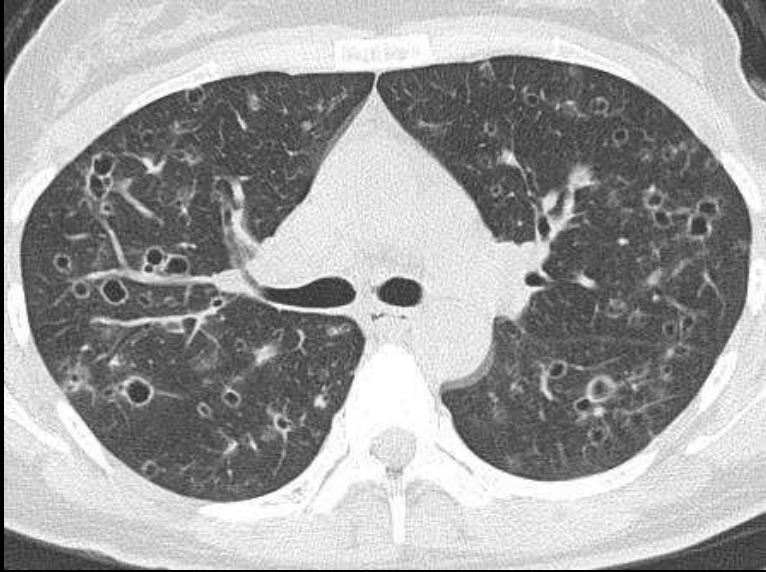
ERECT

L P-

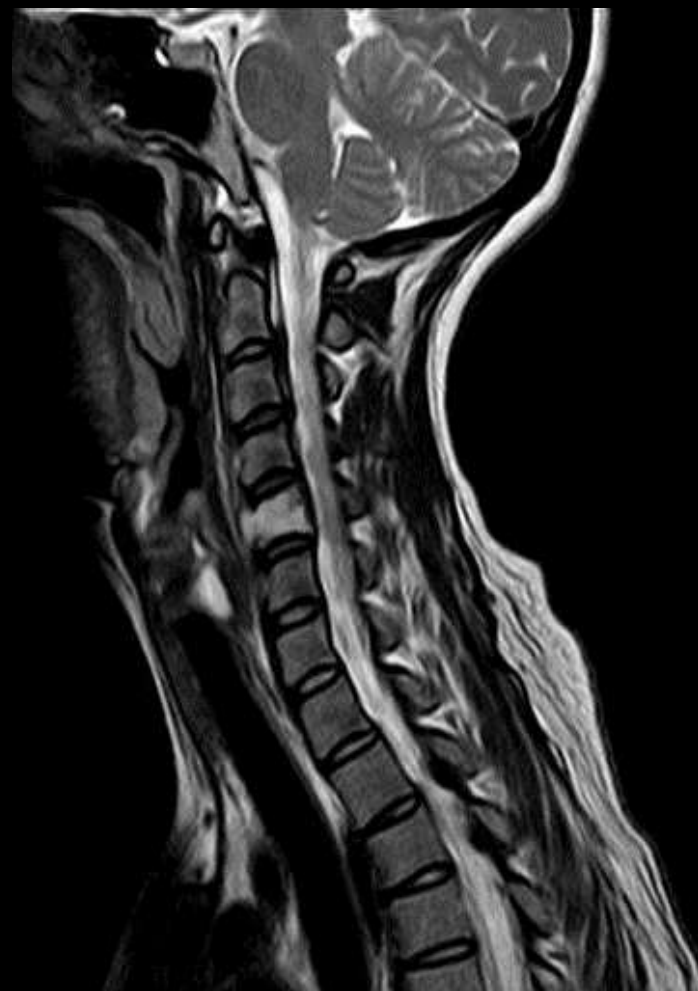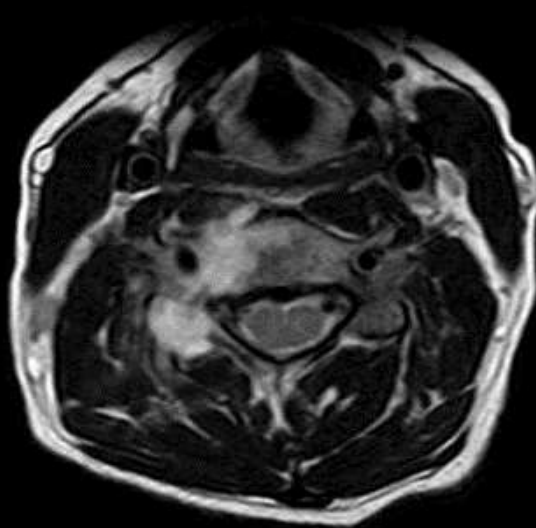
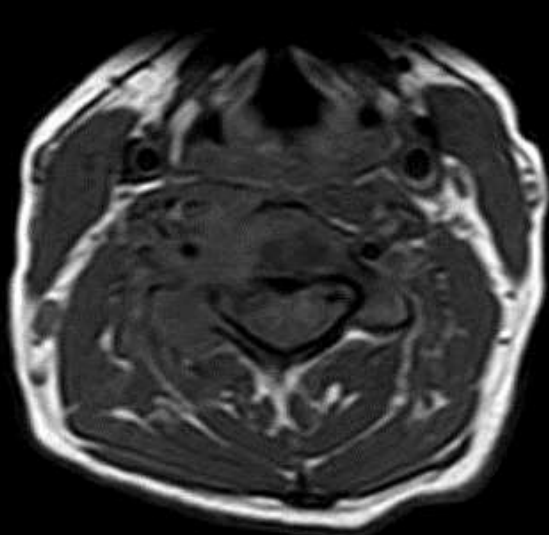


Follow up CT

2か月後

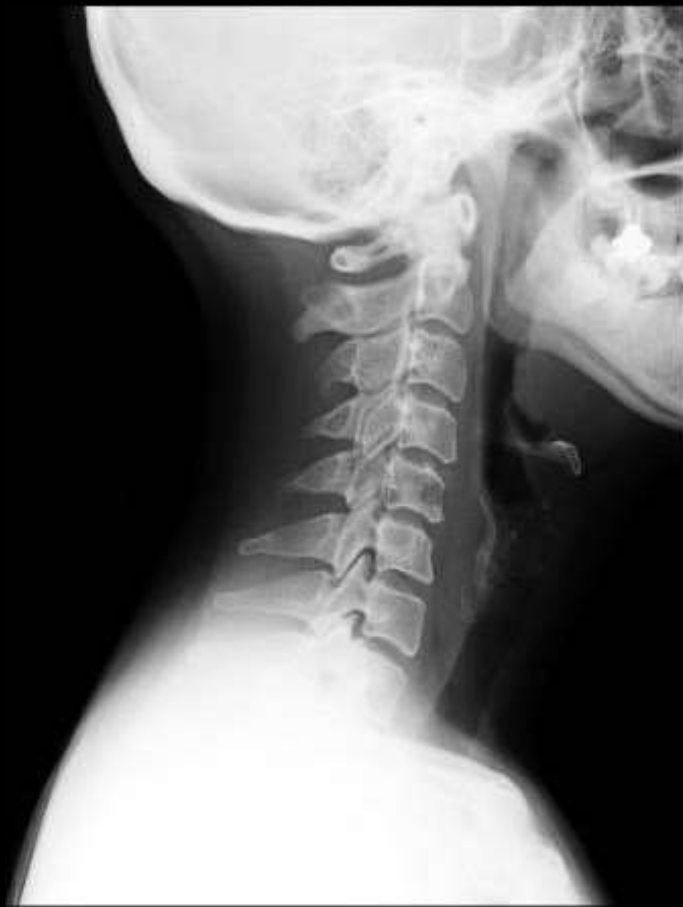
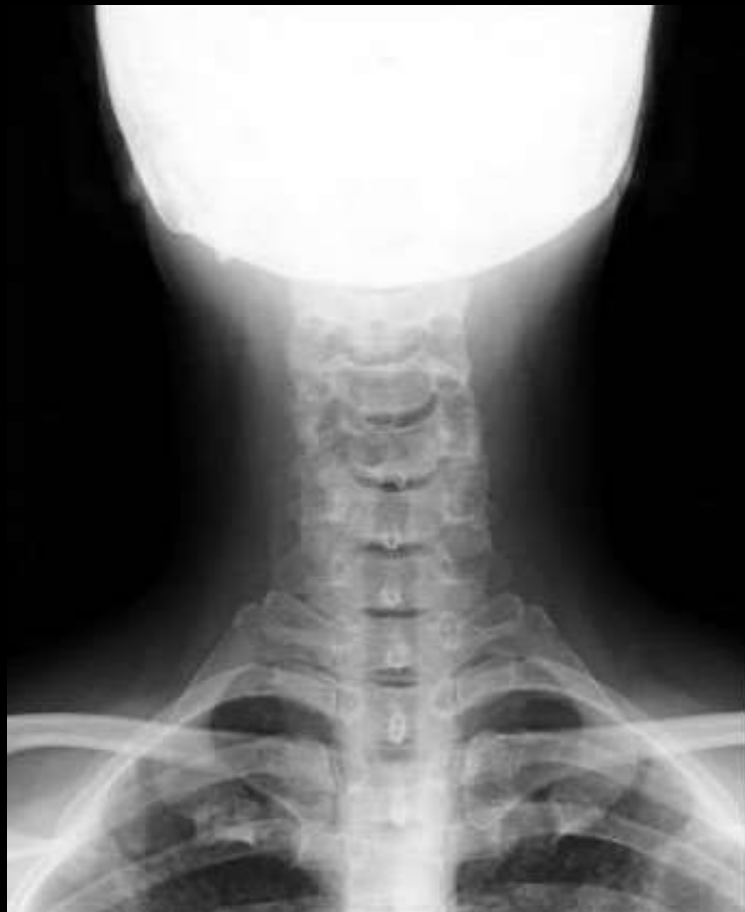
頸椎MRI

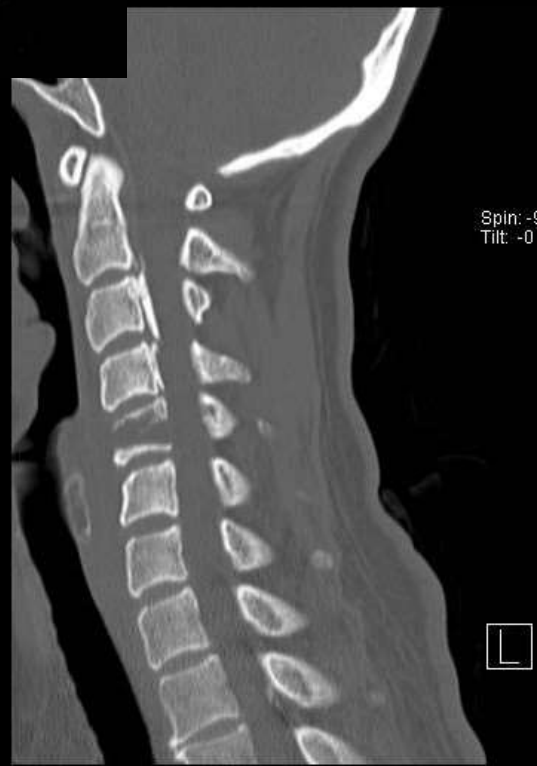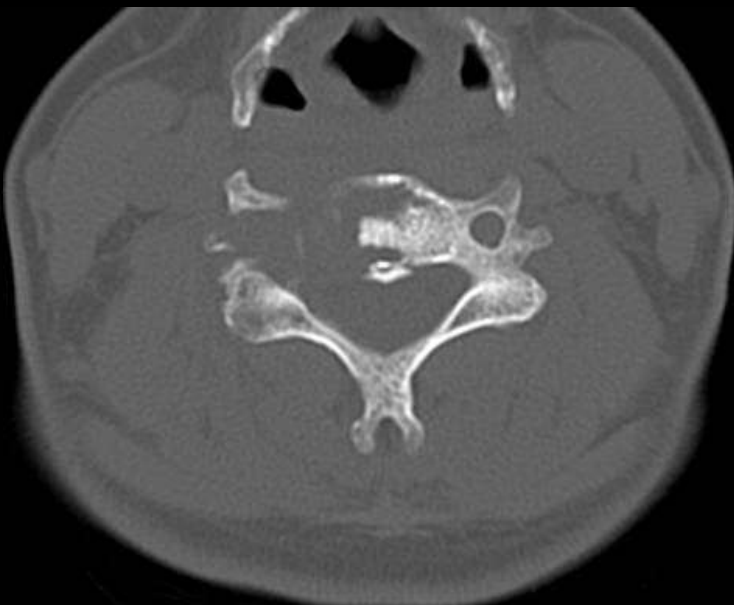
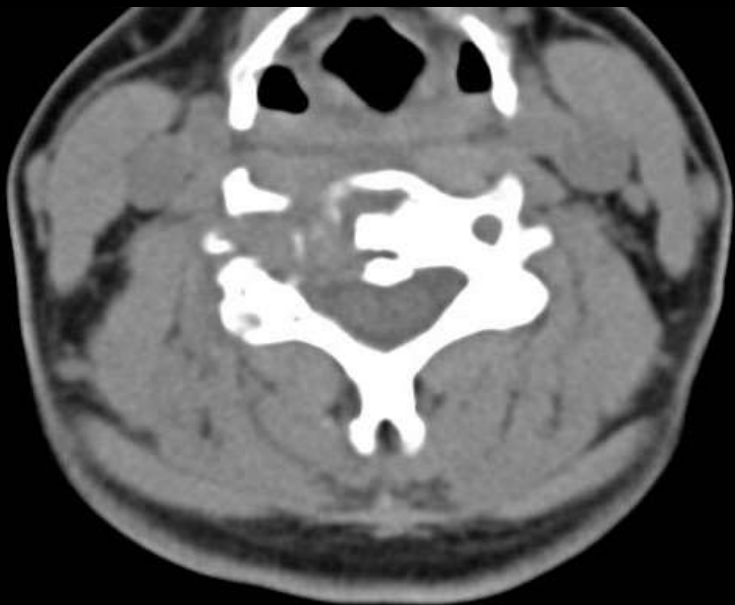


T1-WI, T2-WI, T2-WI

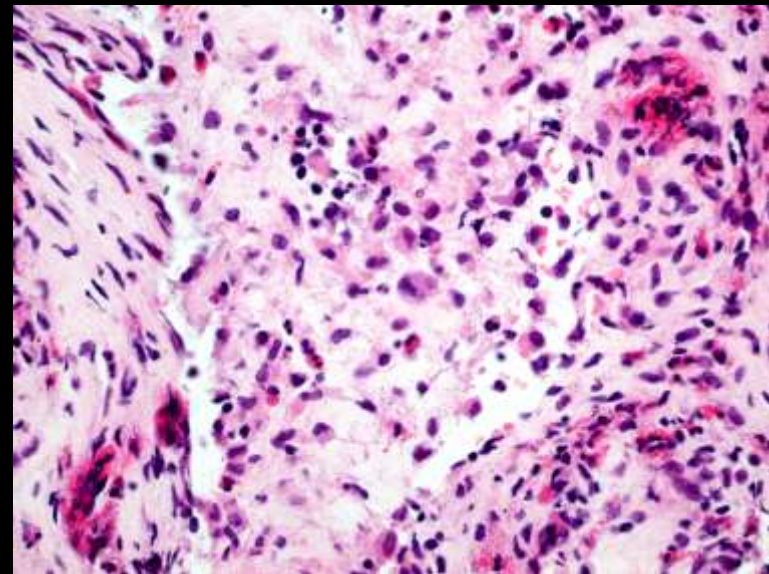
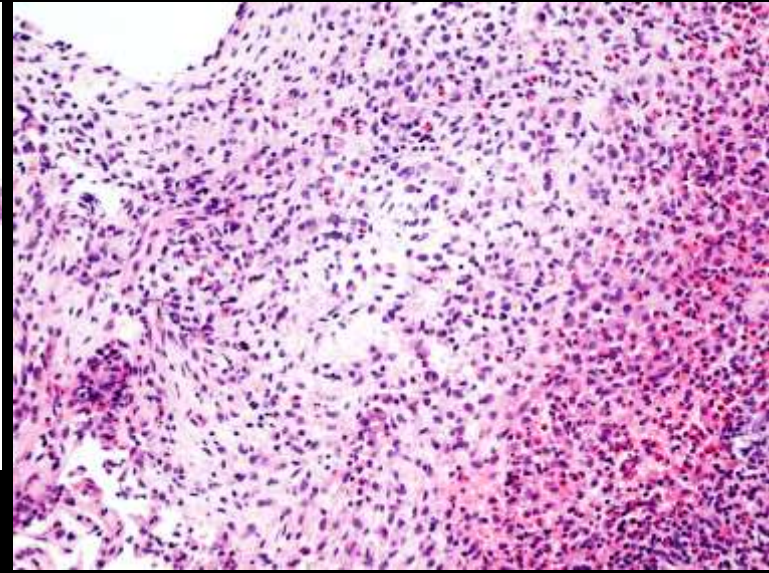
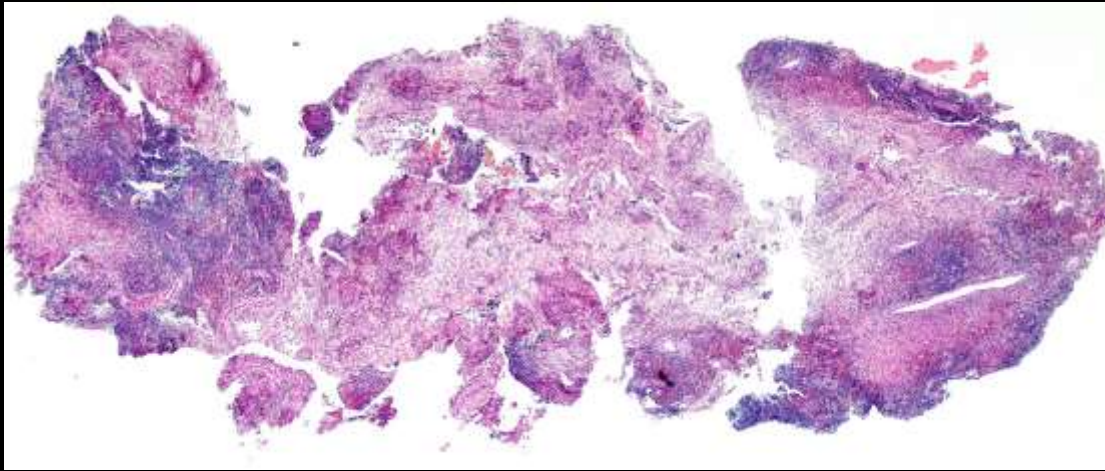
頸椎攝影



頸椎CT



病理組織像



| | |
|-------|-------|
| × 20 | × 200 |
| × 400 | |