単純CT

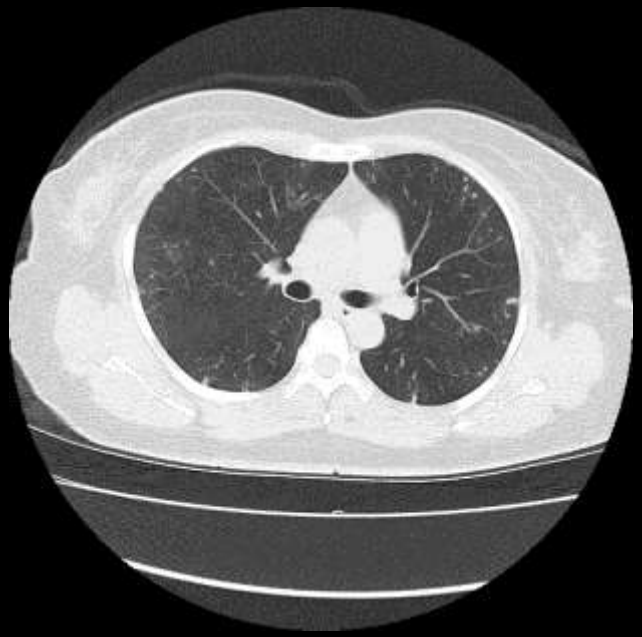

動脈後期相

門脈相

後期動脈相coronal

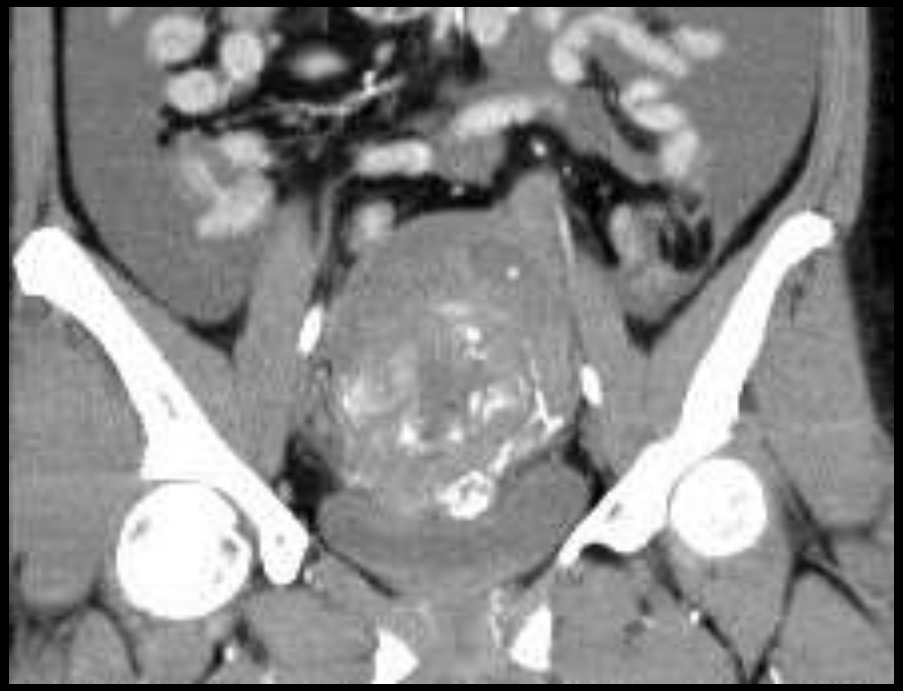

門脈相sagittal