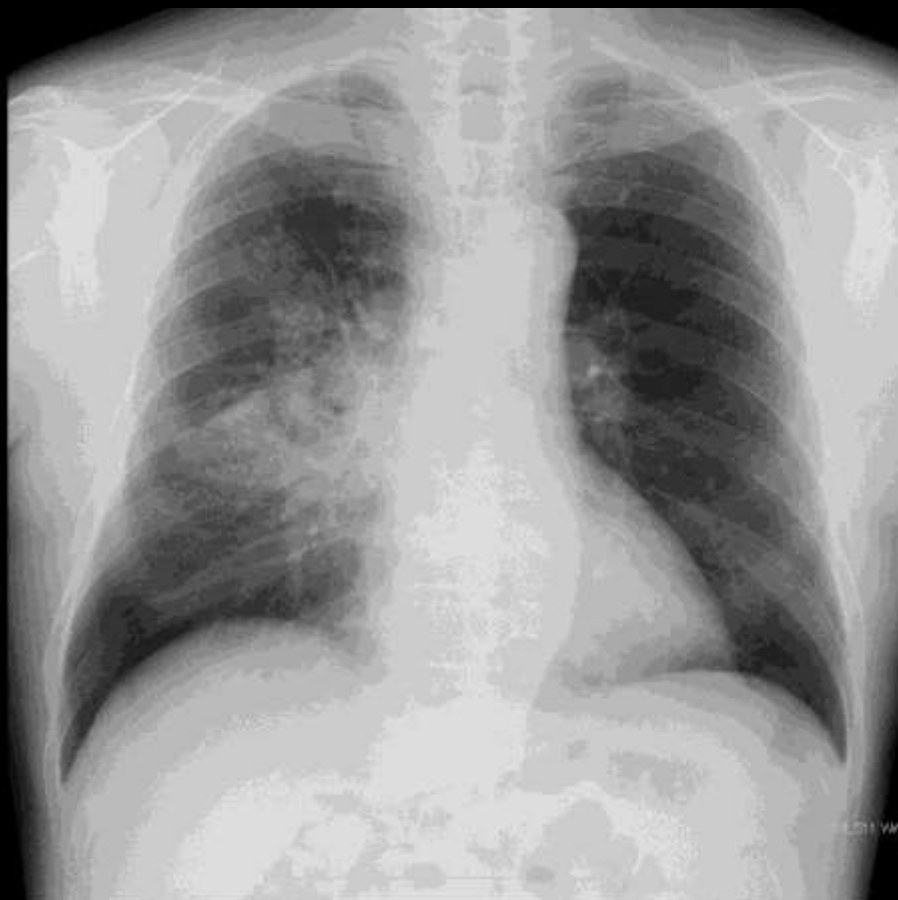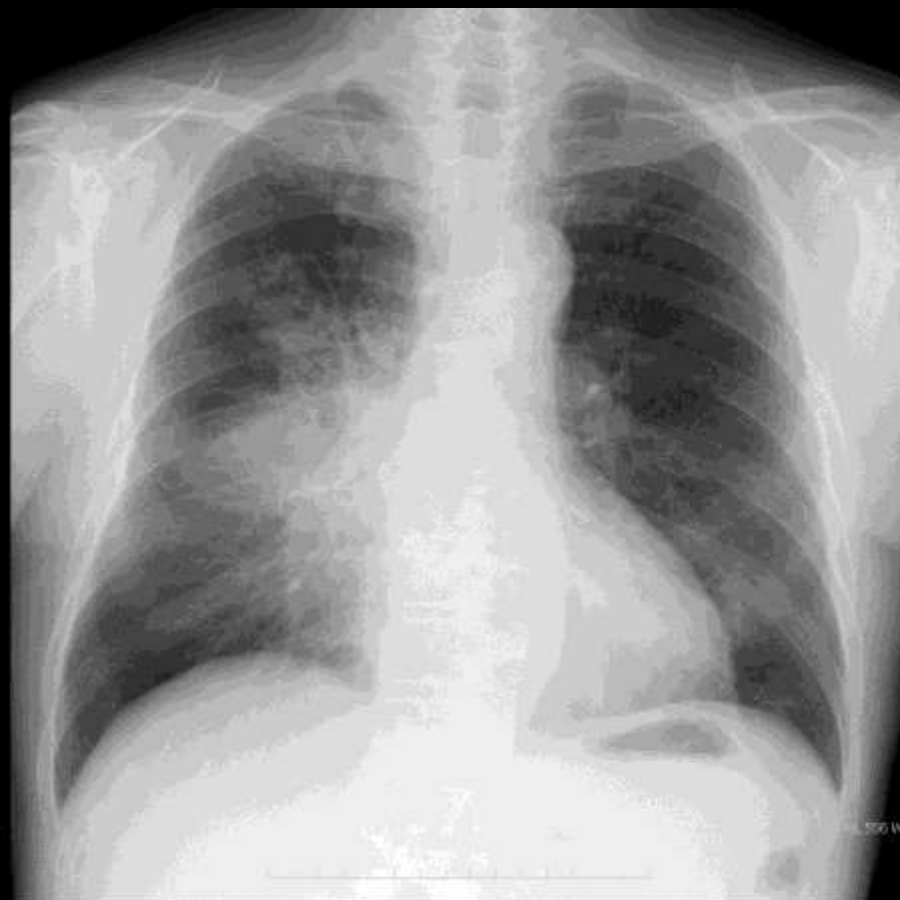


胸部単純X線

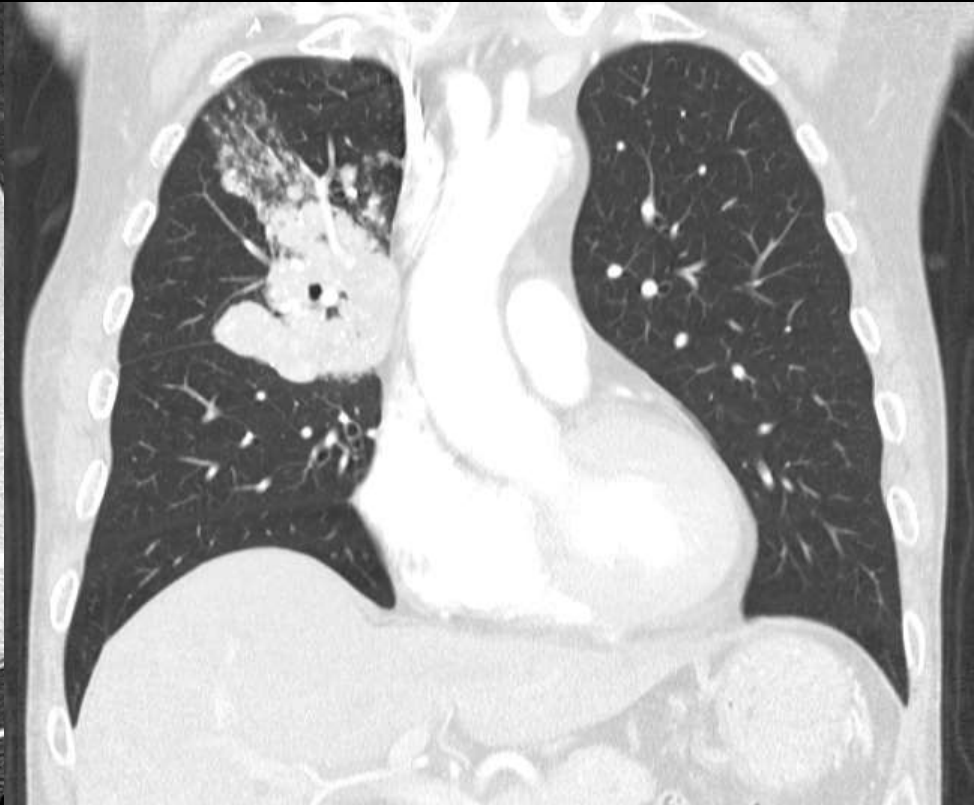
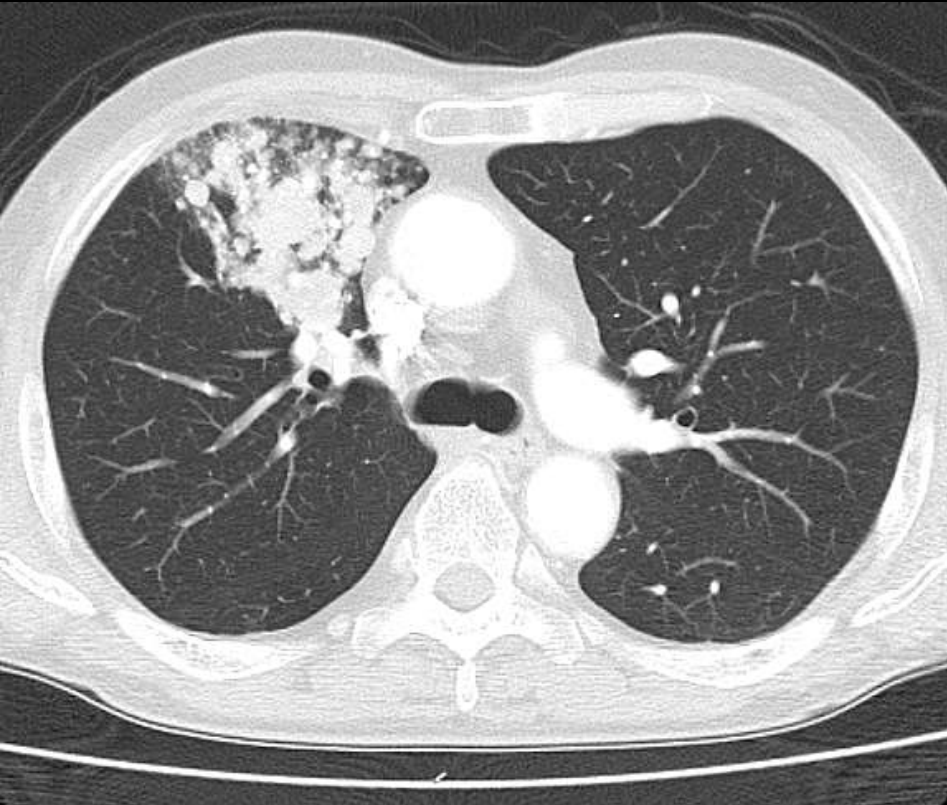


当院受診時

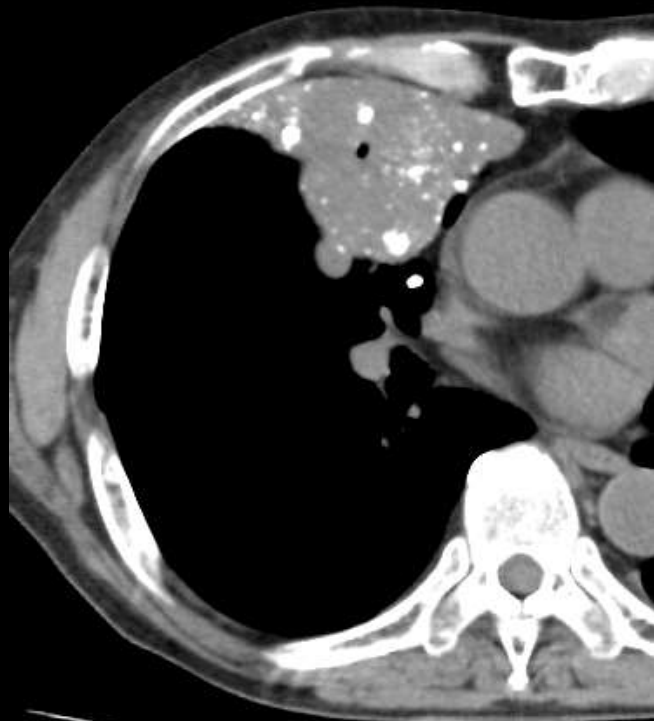


5年前他院検査

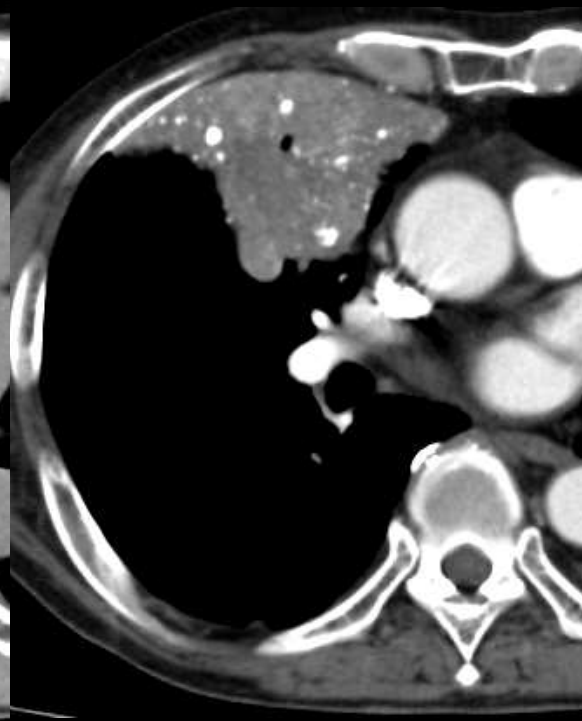CT Key画像-1



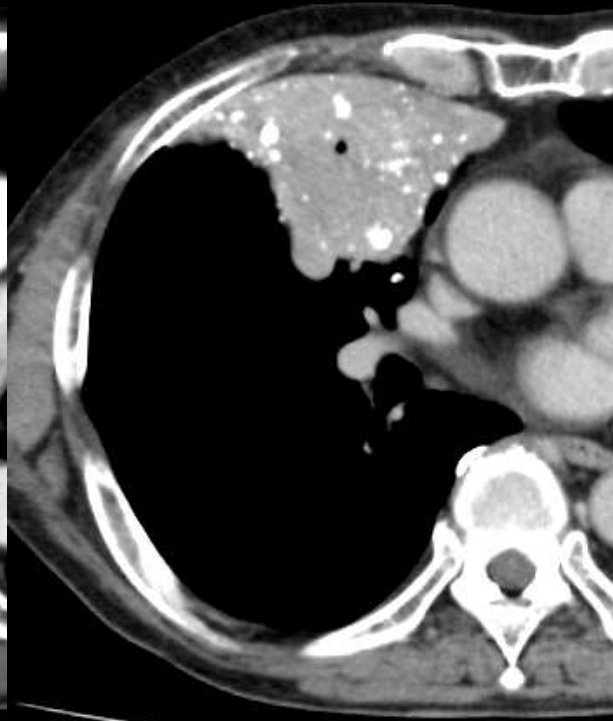
CT Key画像-2



単純CT

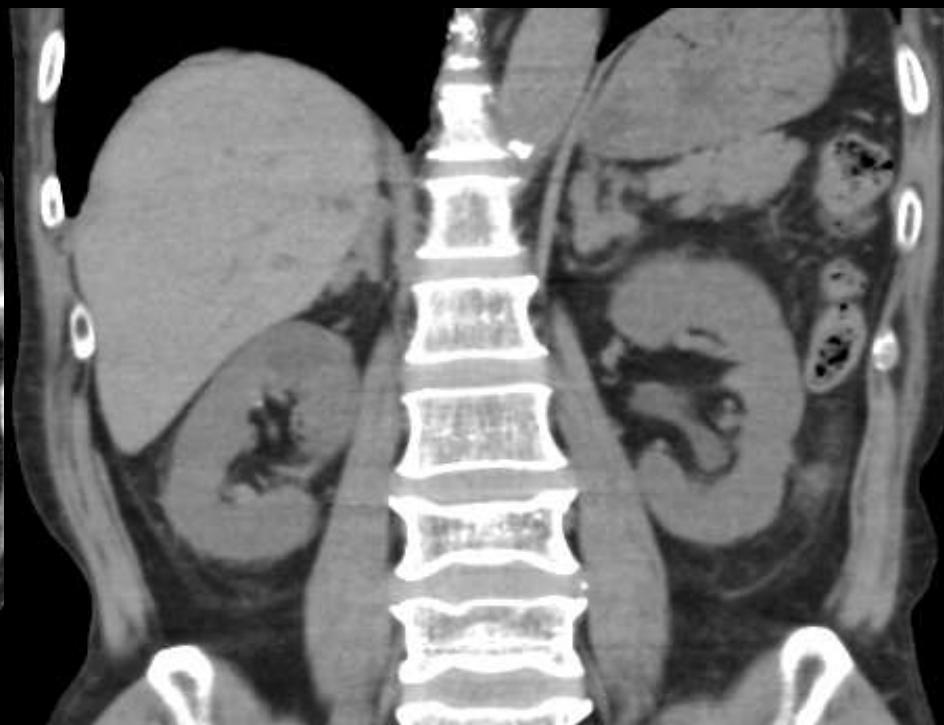
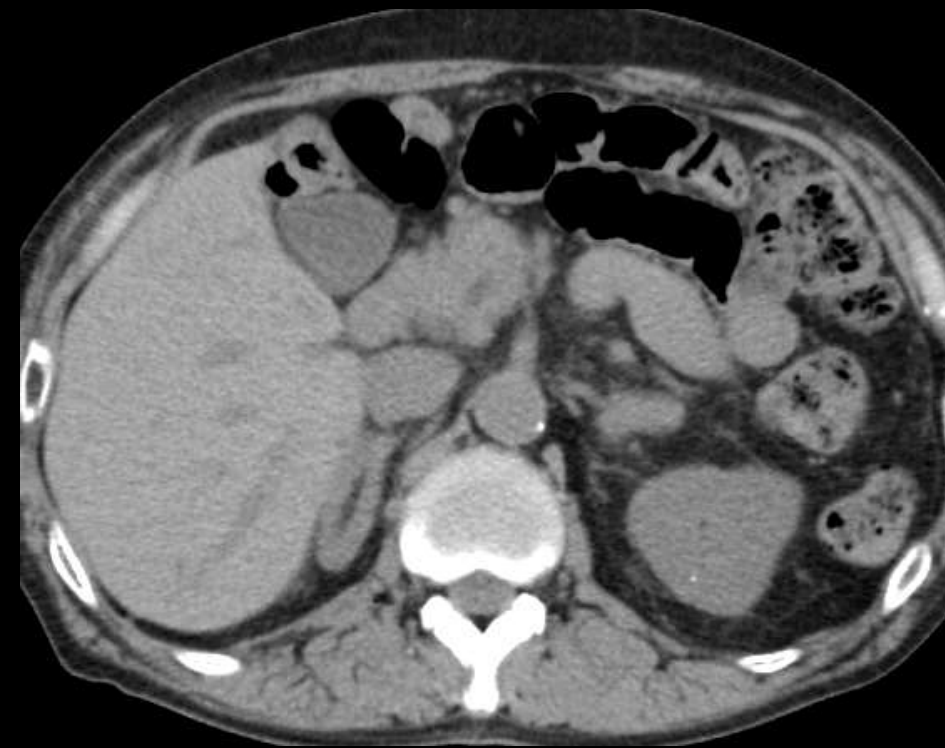


造影CT動脈相

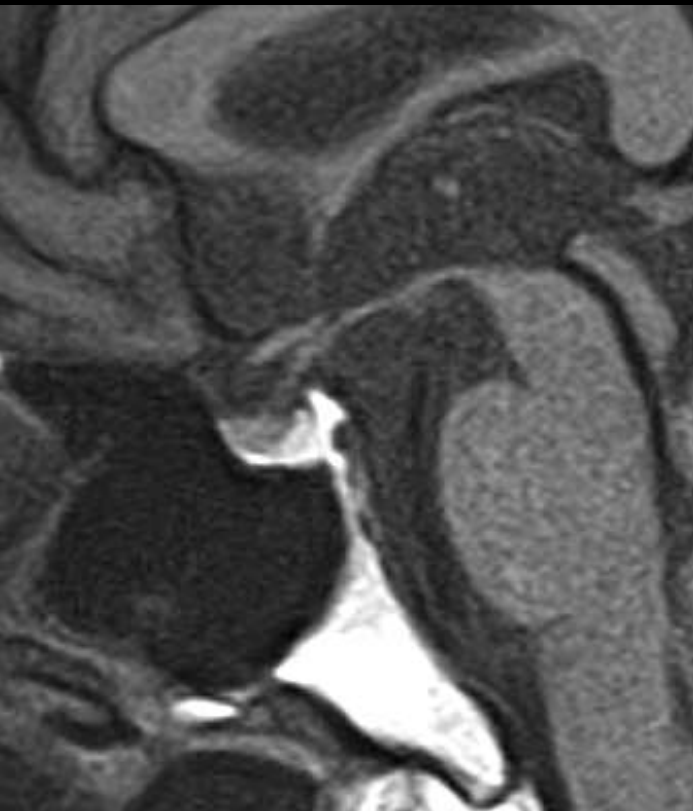


造影CT実質相

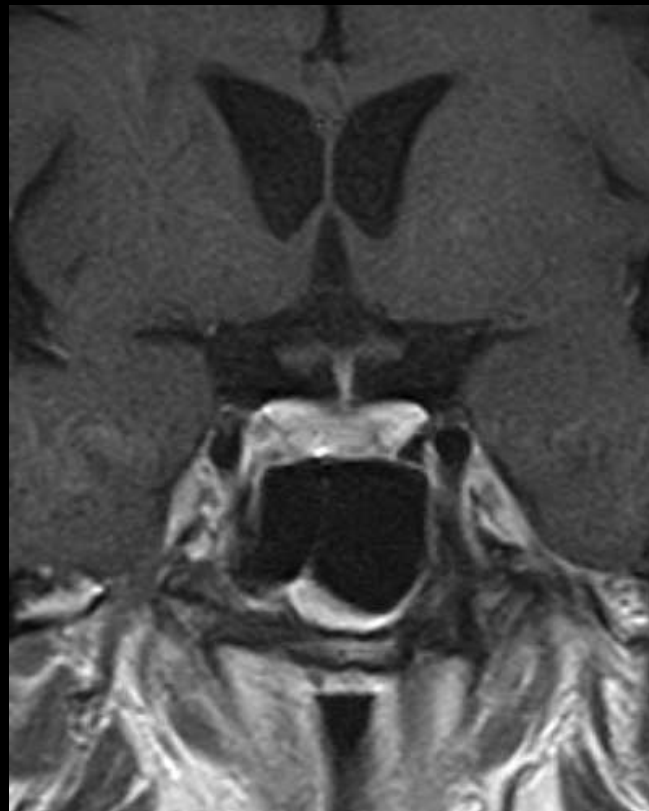
CT Key画像-3



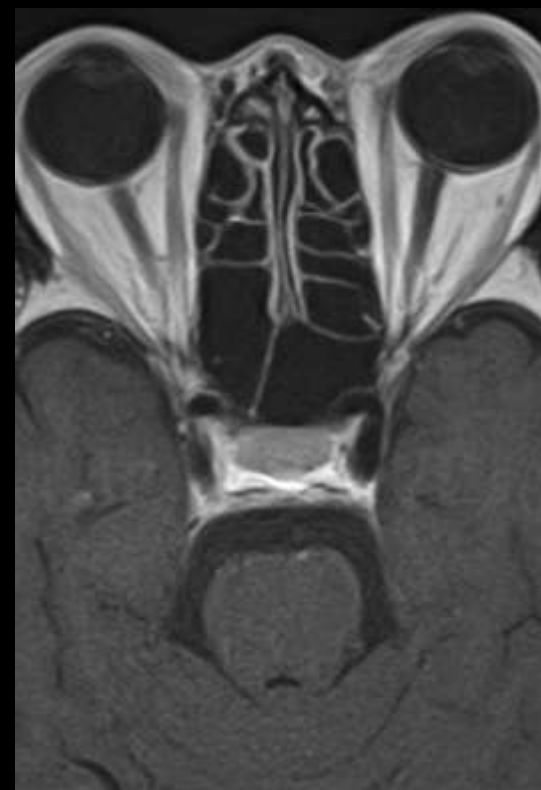CT Key画像-4



単純T1WI

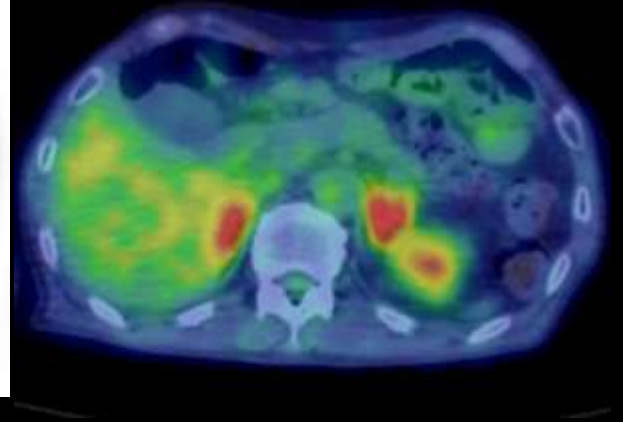
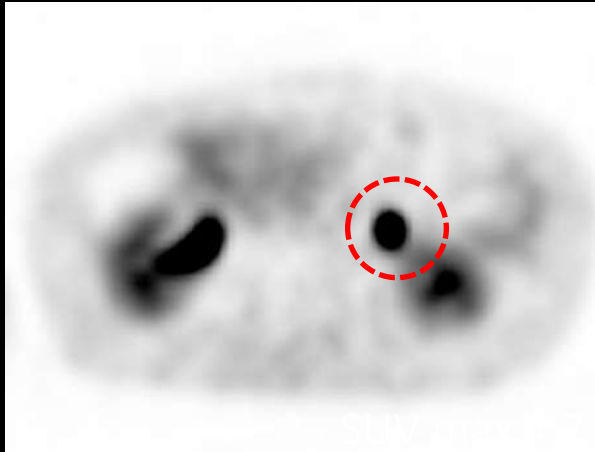
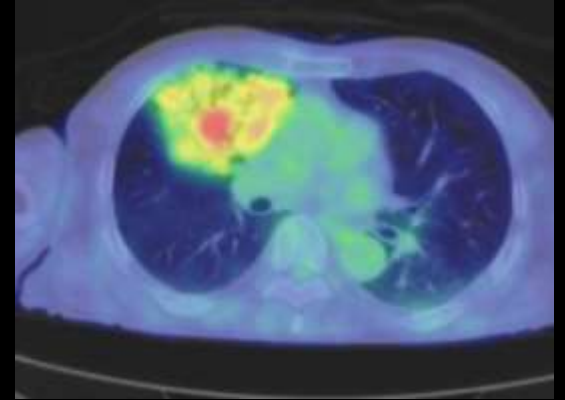
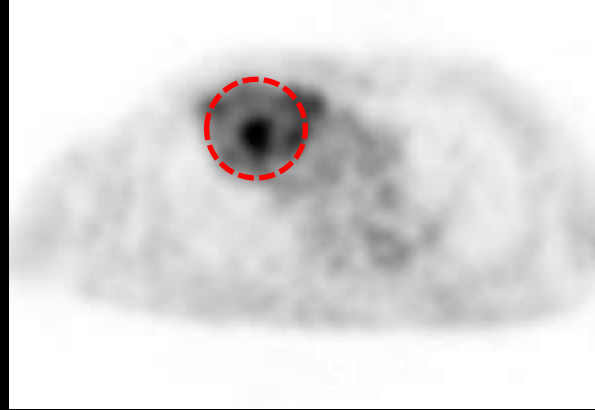
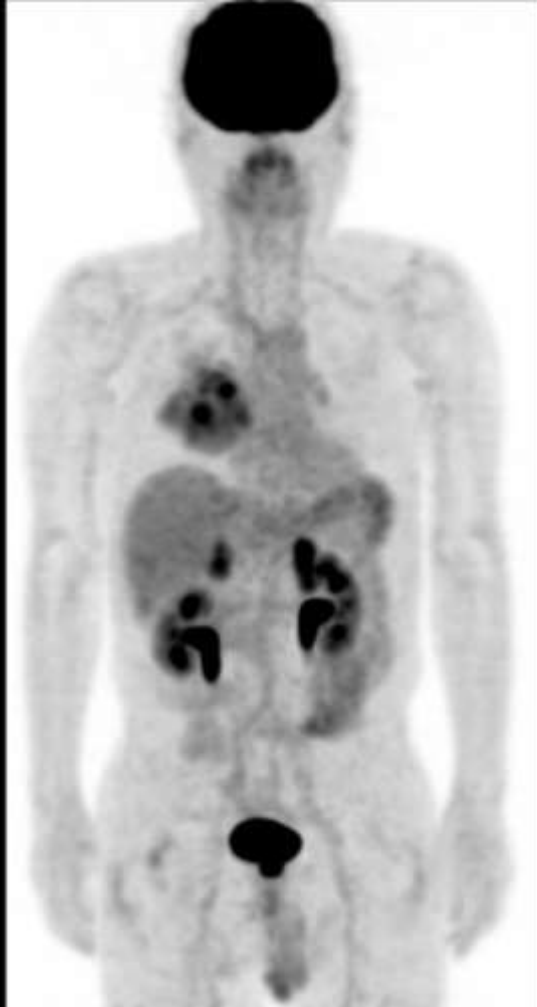
造影T1WI



造影T1WI

CT Key画像-5



胸部CT經時的變化

