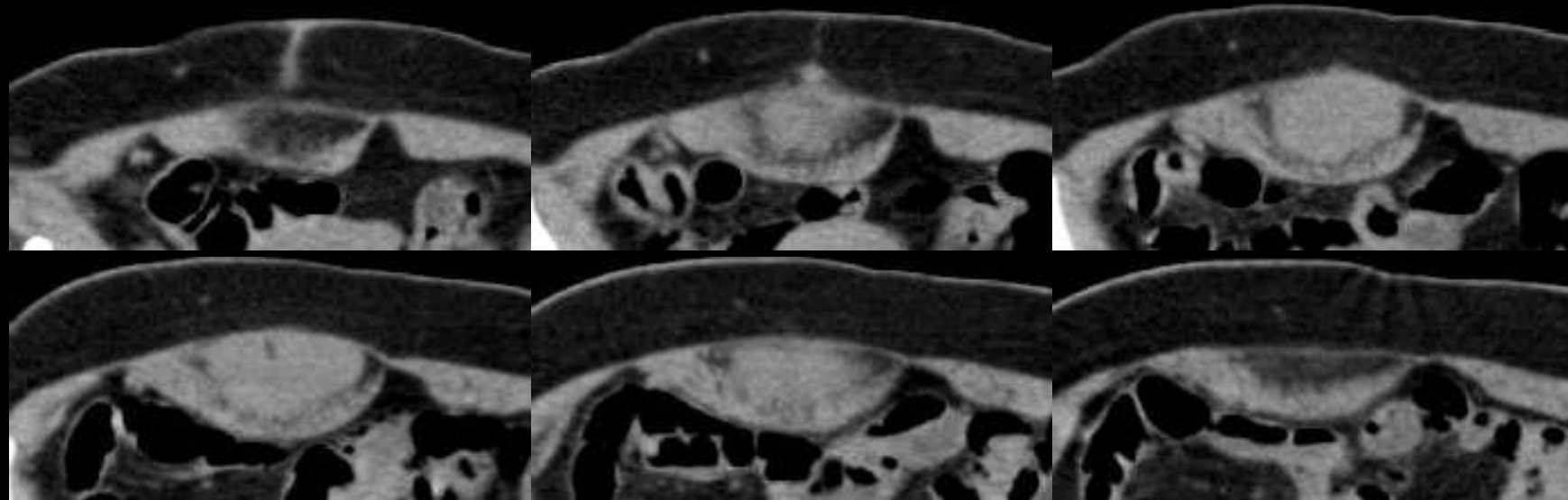
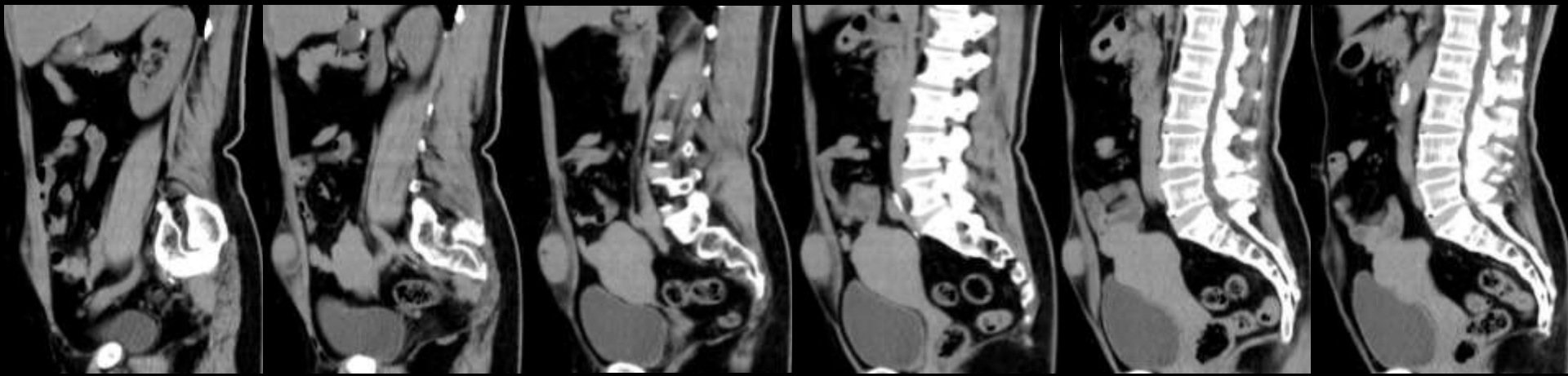


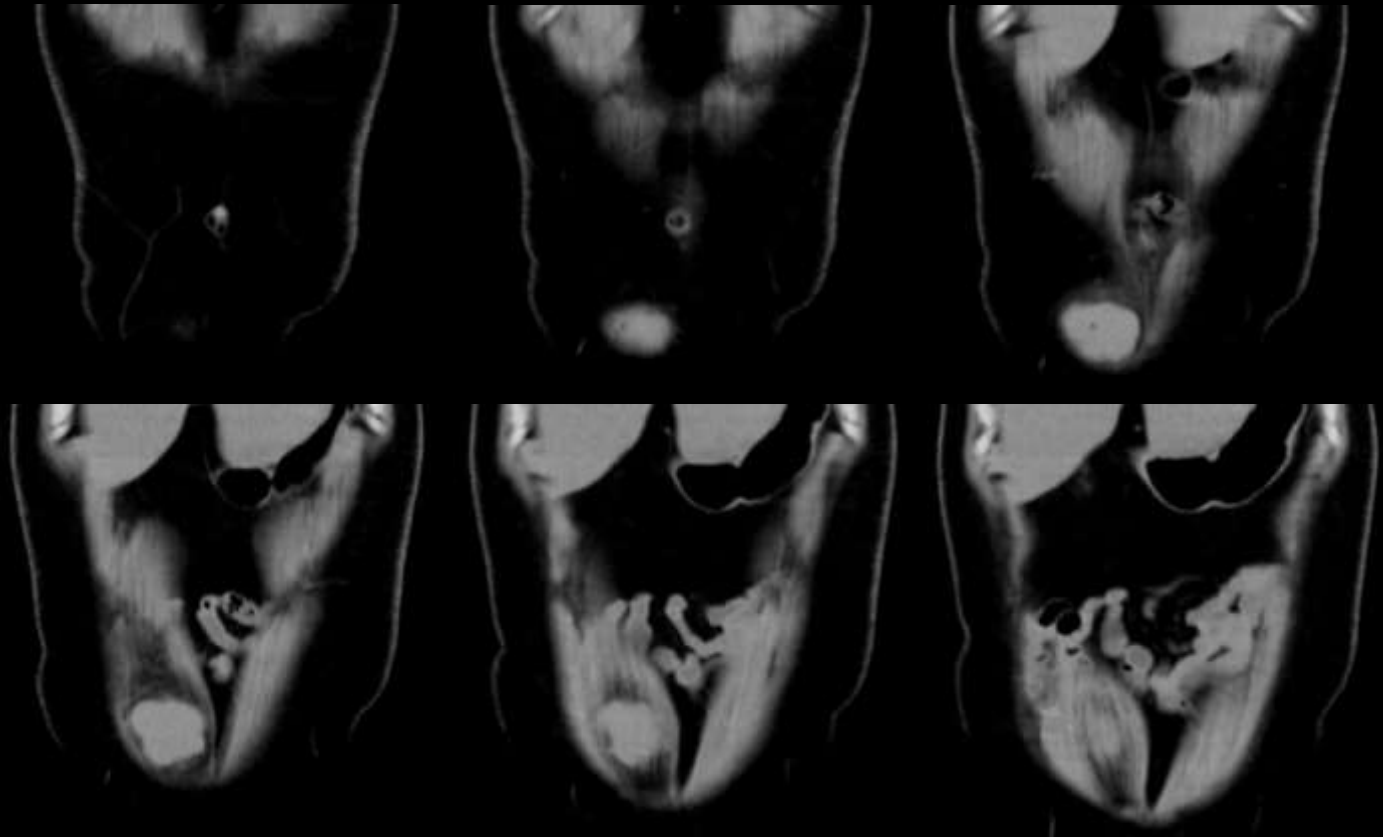
腹部単純CT Axial



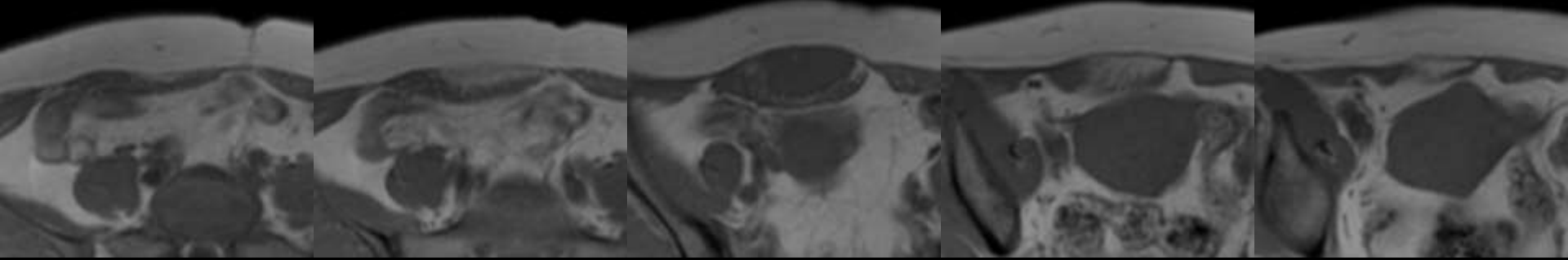
腹部単純CT Sagittal



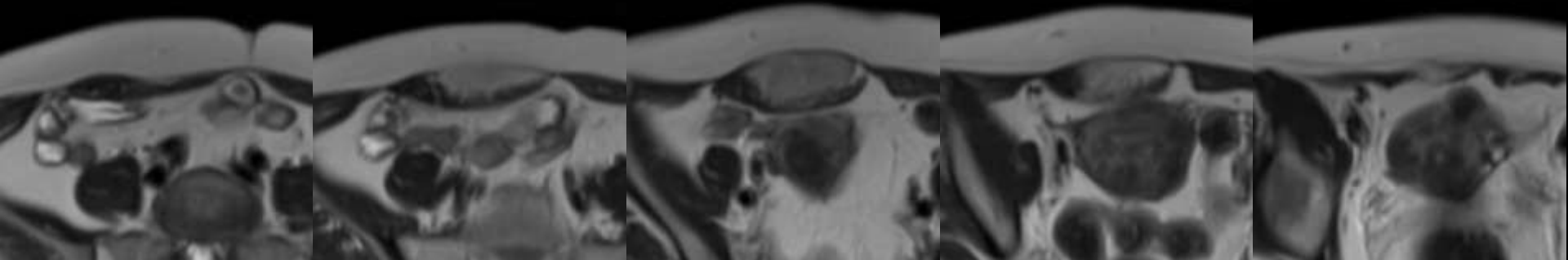
腹部単純CT
Coronal



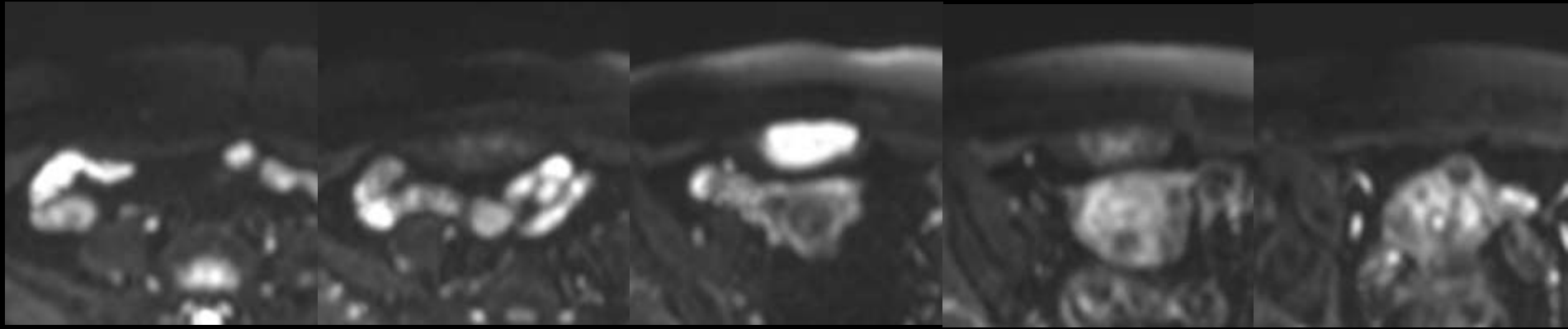
MRI Axial T1WI



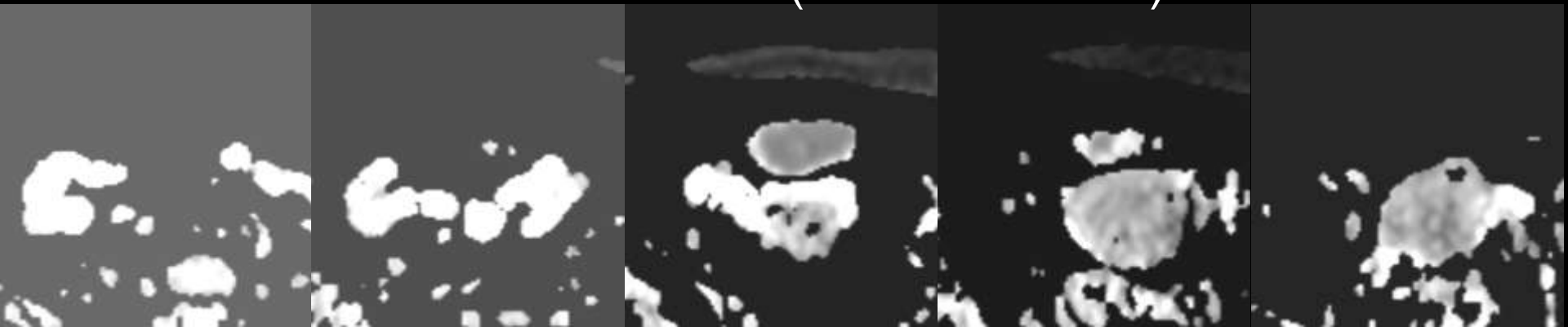
MRI Axial T2WI



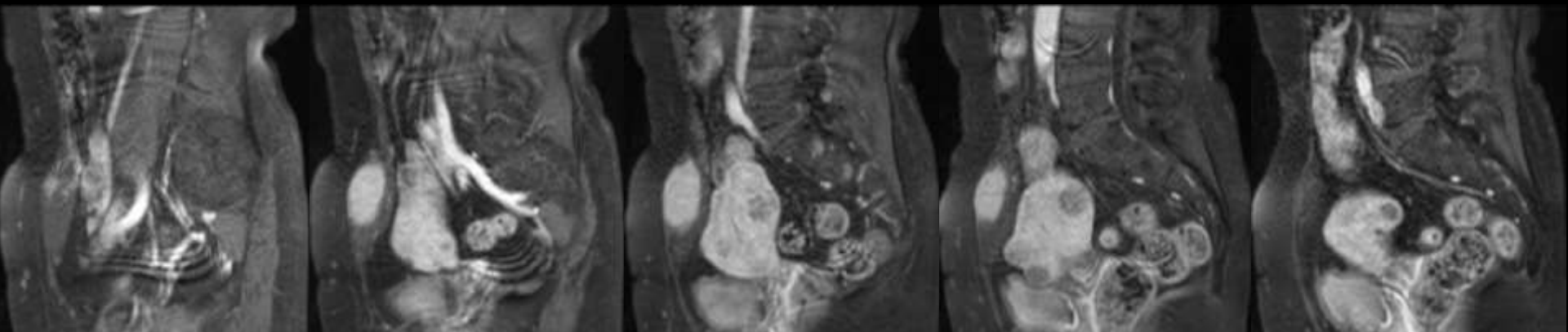
MRI Axial DWI b=800



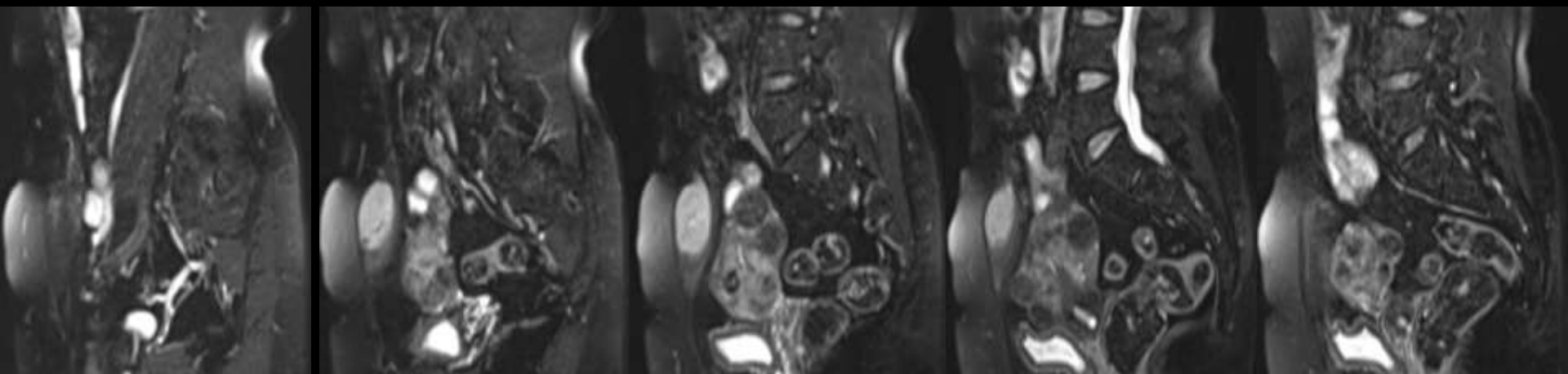
MRI Axial ADC (0.839mm²/sec)

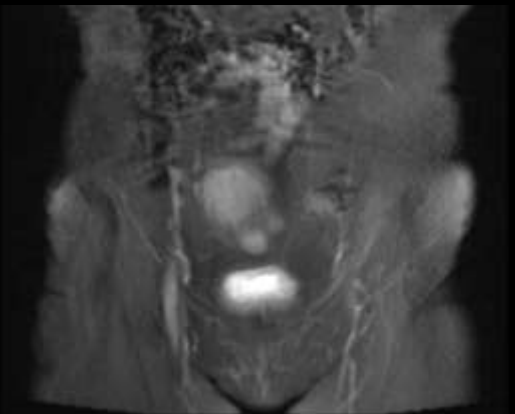
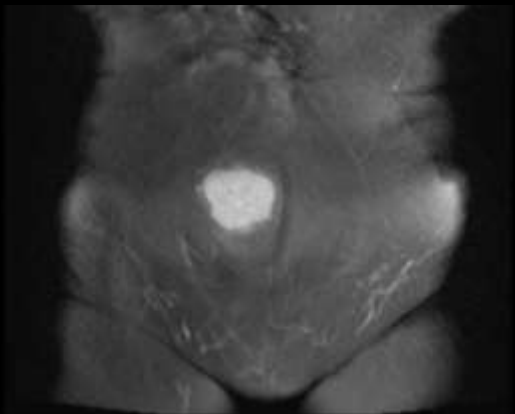
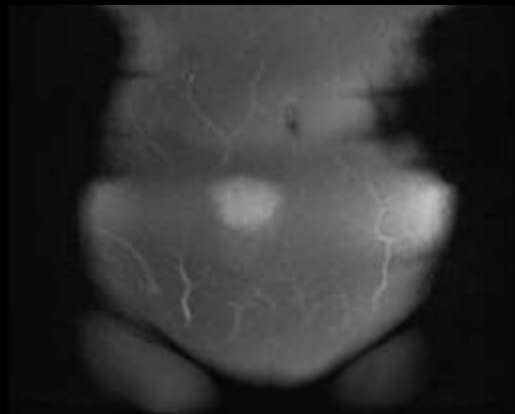


MRI Sagittal Gd-fs-T1WI

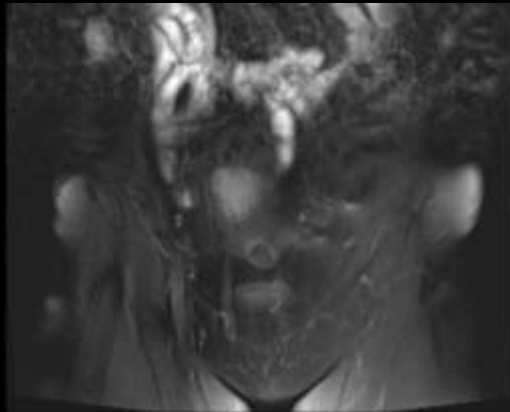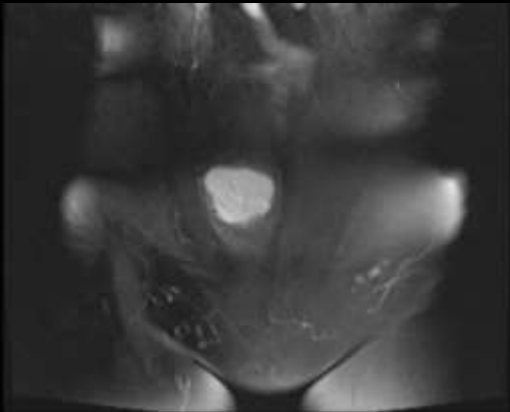
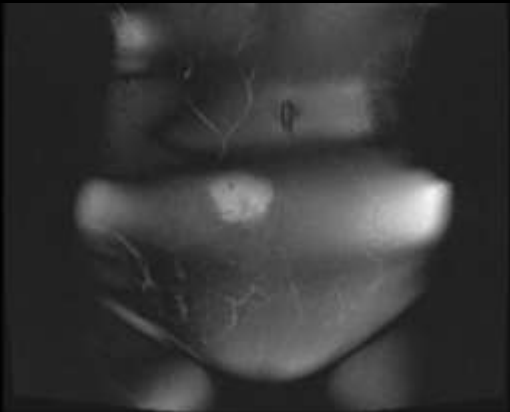


MRI Sagittal Fs-T2WI





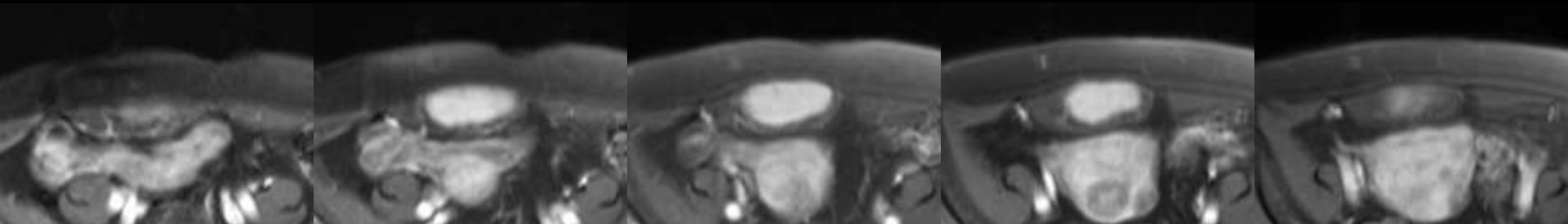
MRI Coronal Gd-fs-T1WI



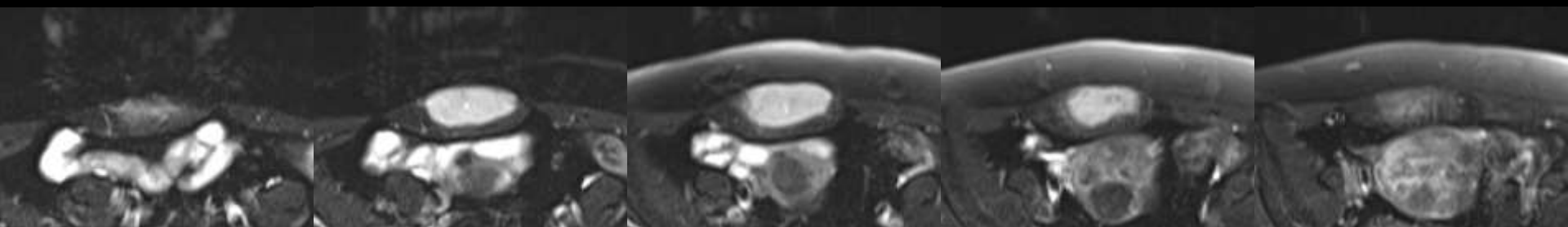
MRI Coronal Fs-T2WI

Gd-fs-T1WI

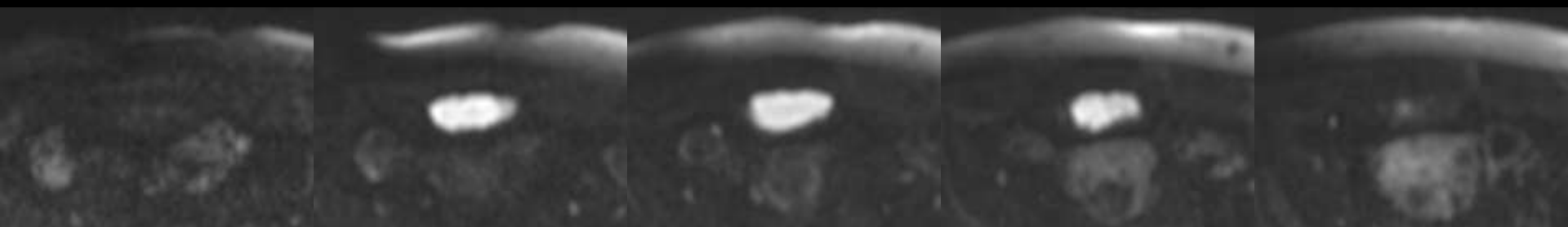MRI Axial



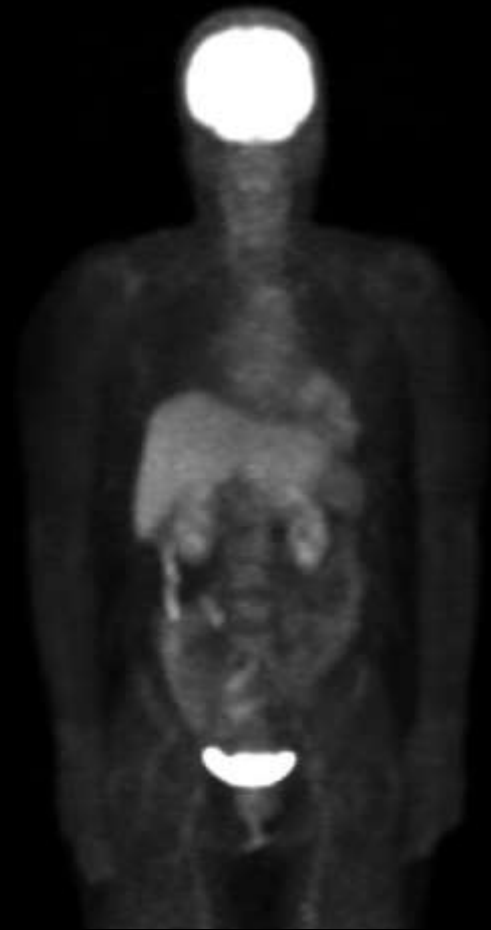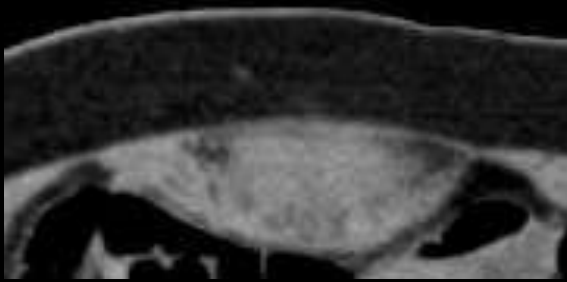

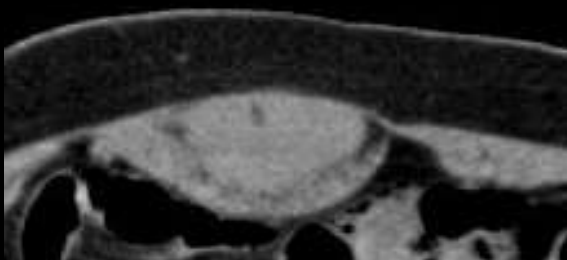

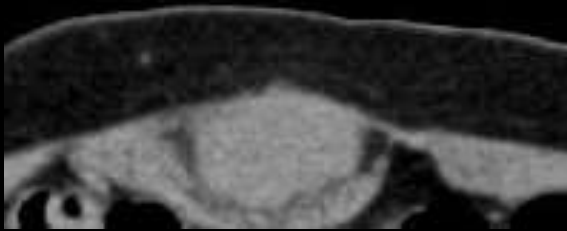
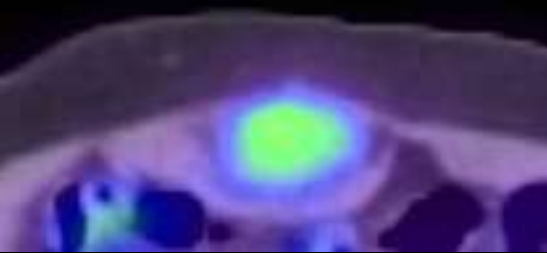
Fs-T2WI



DWI b=800



FDG-PET/CT



MIP