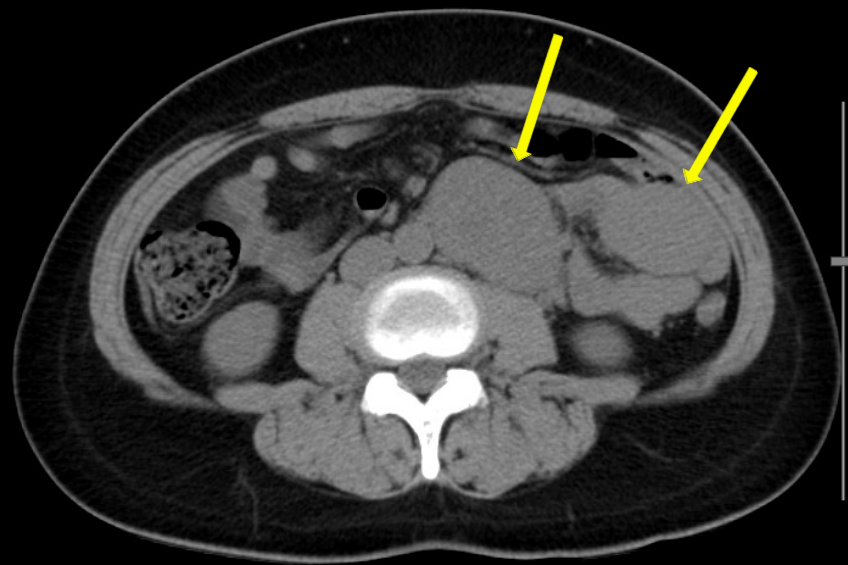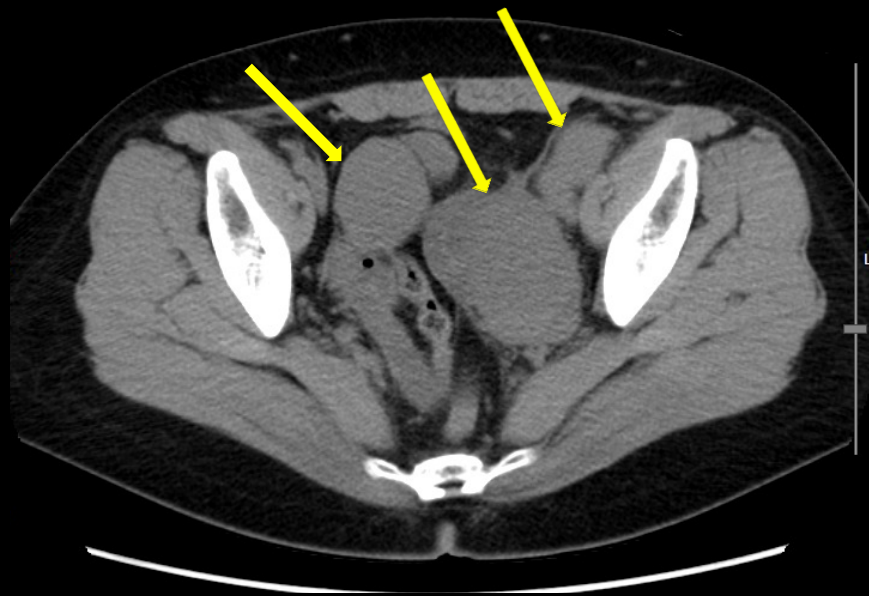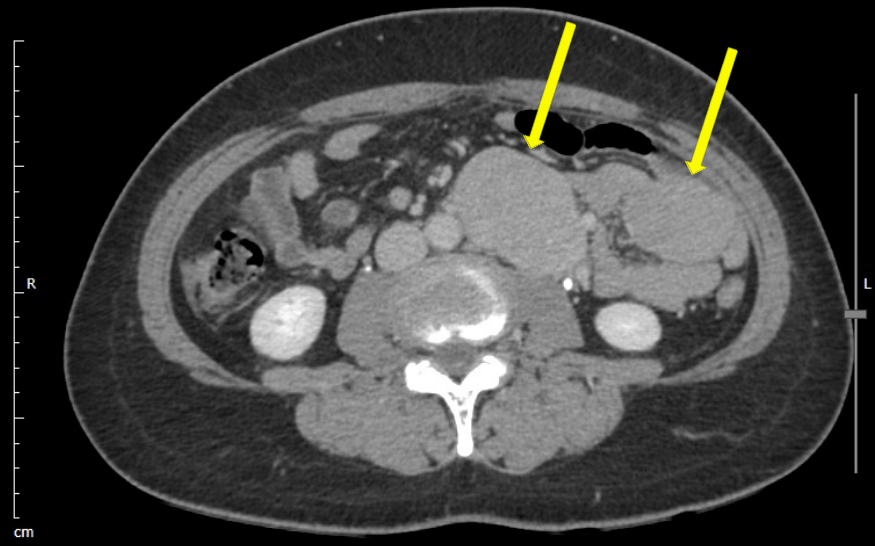
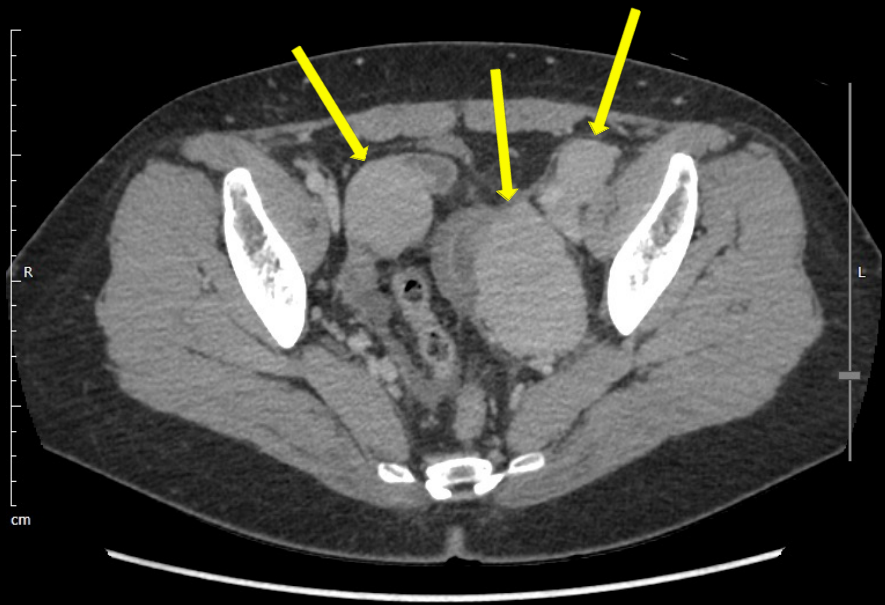
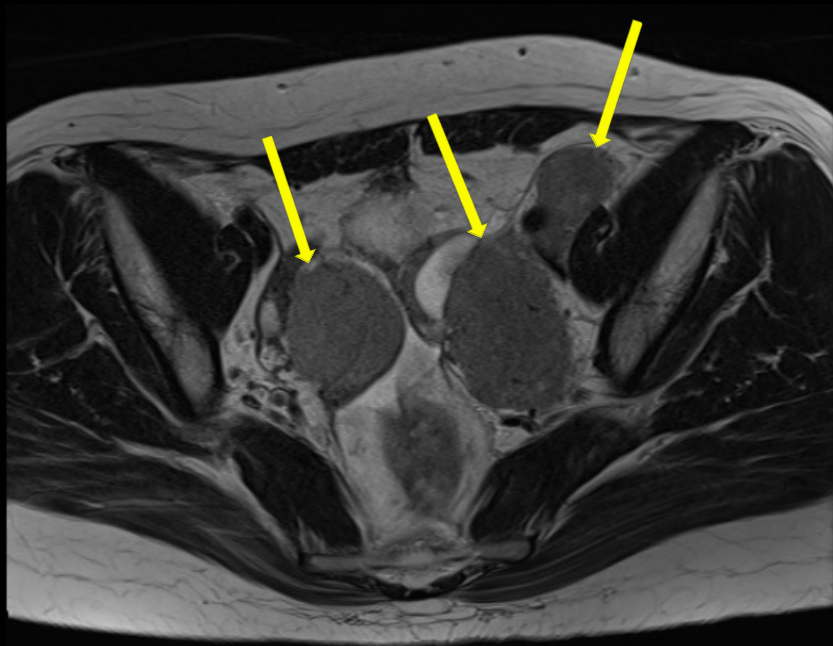


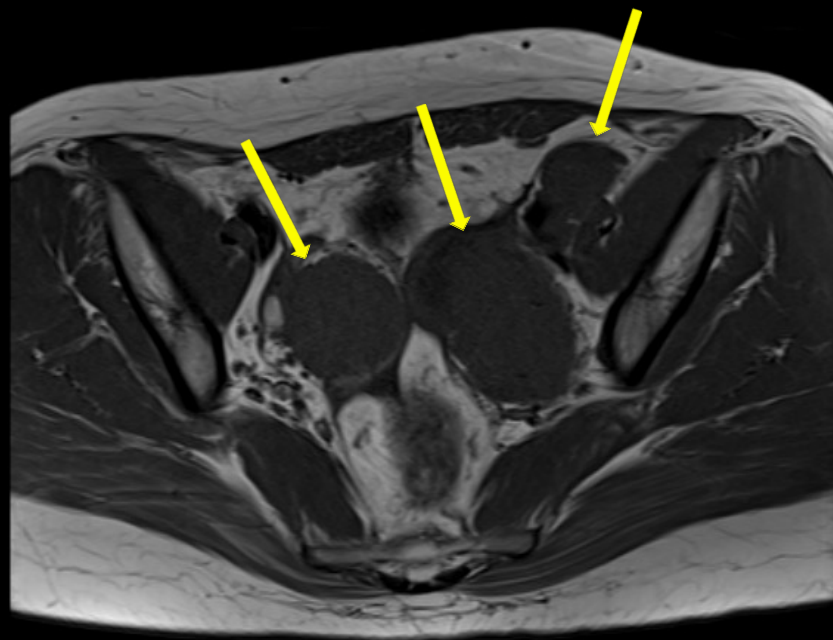
単純CT axi



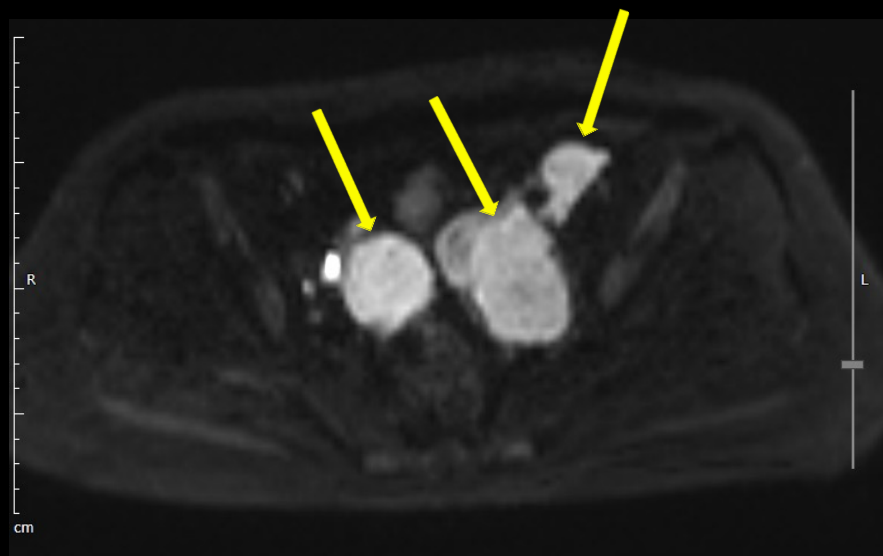
造影CT axi



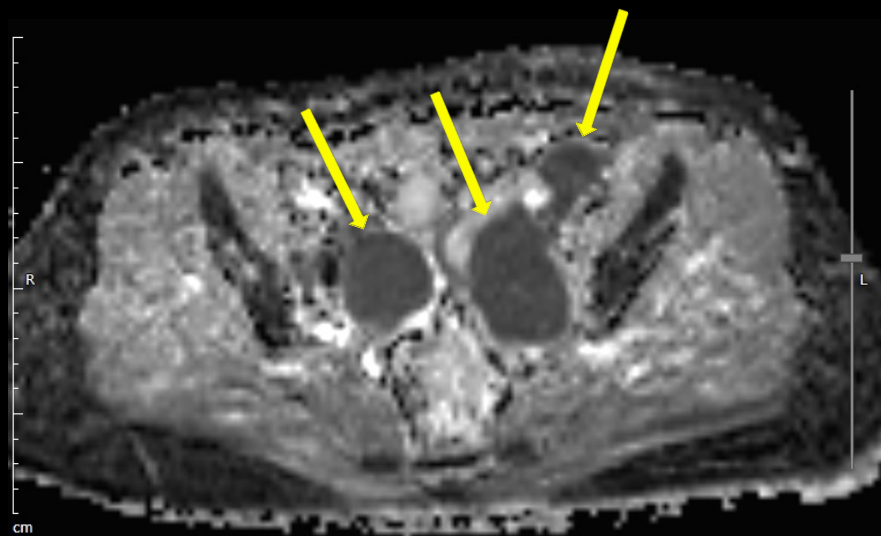
T2WI axi



T1WI axi

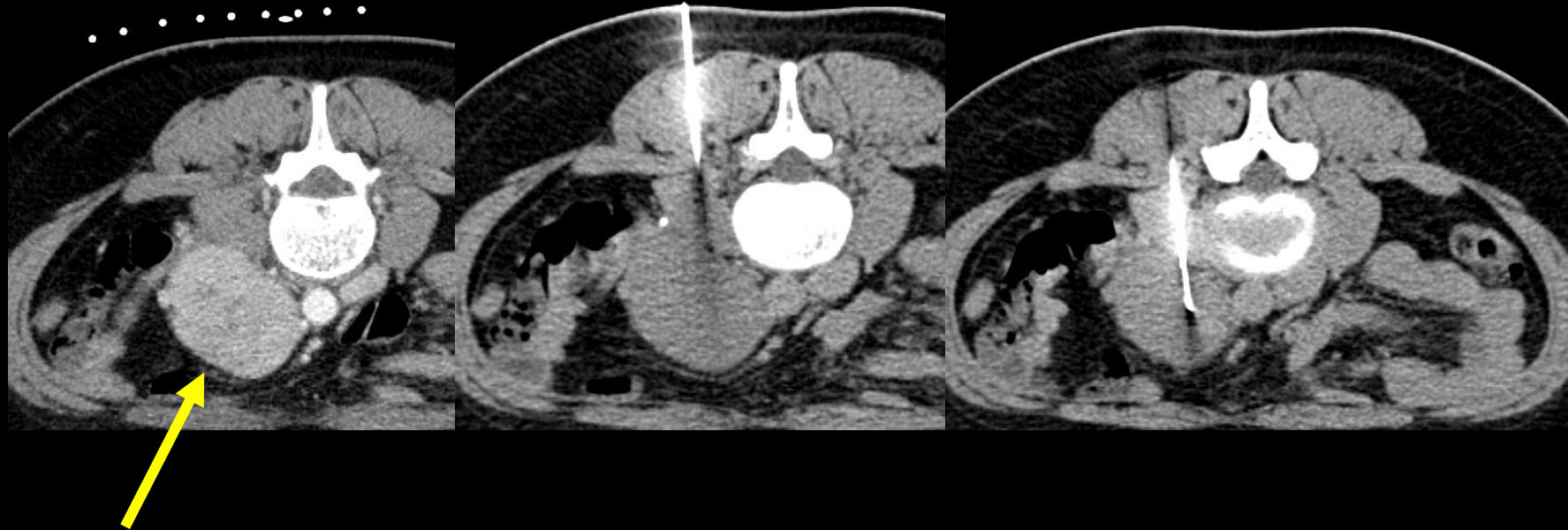


DWI axi

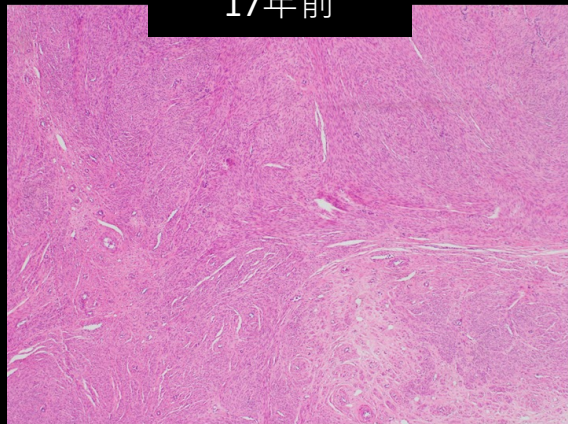


ADC map

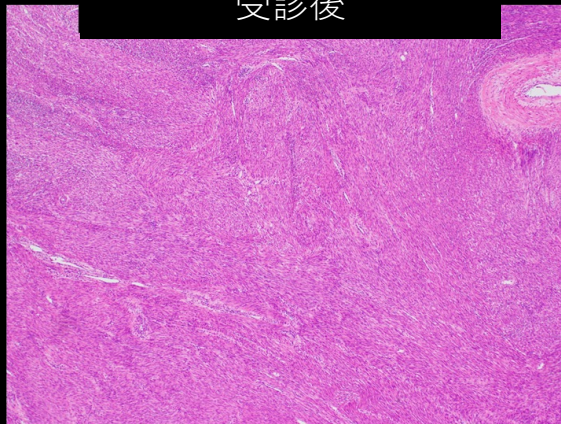
生検CT



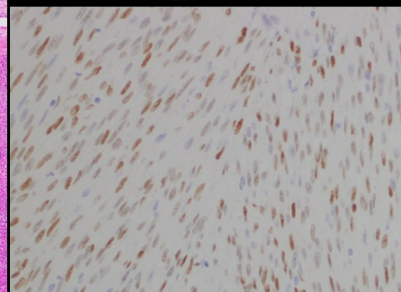
17年前



受診後



ER



Ki-67(陽性率10%)

