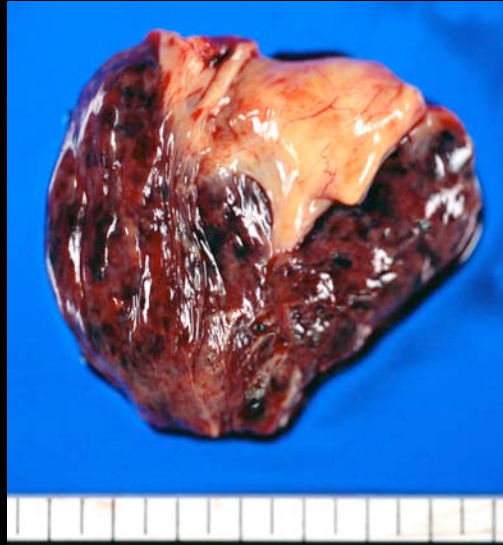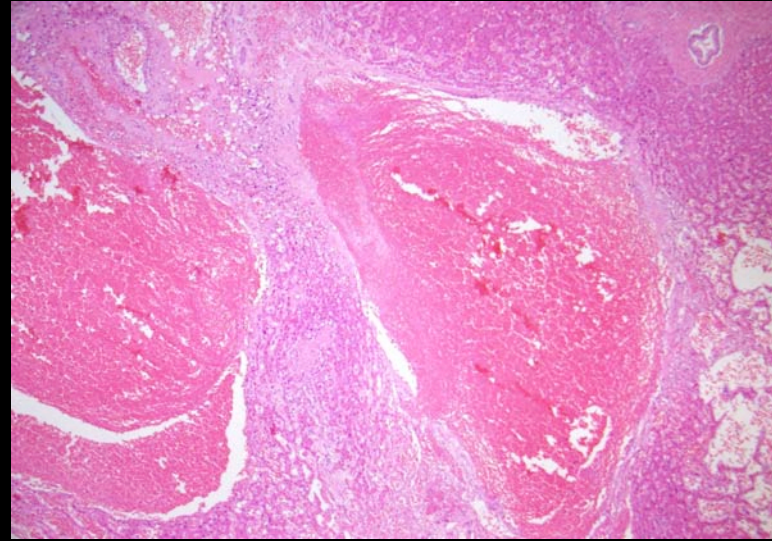


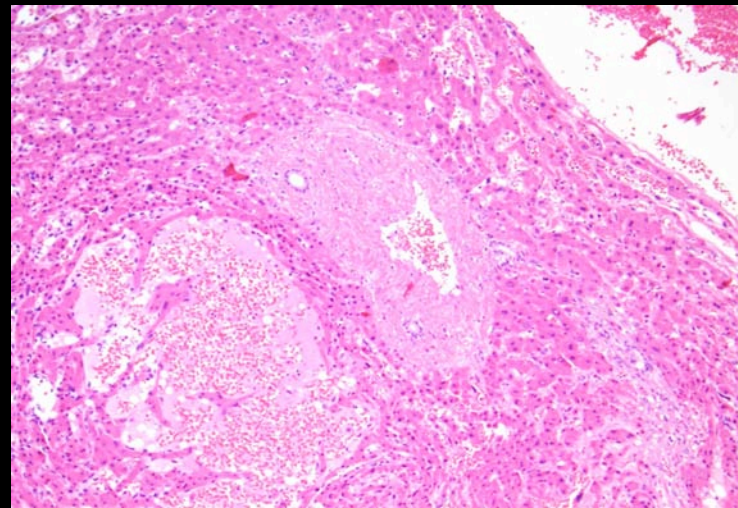
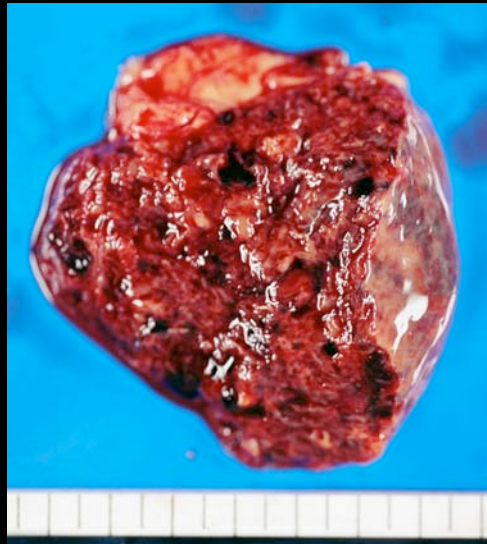剖検肝 肉眼所見



組織像 (HE x4)

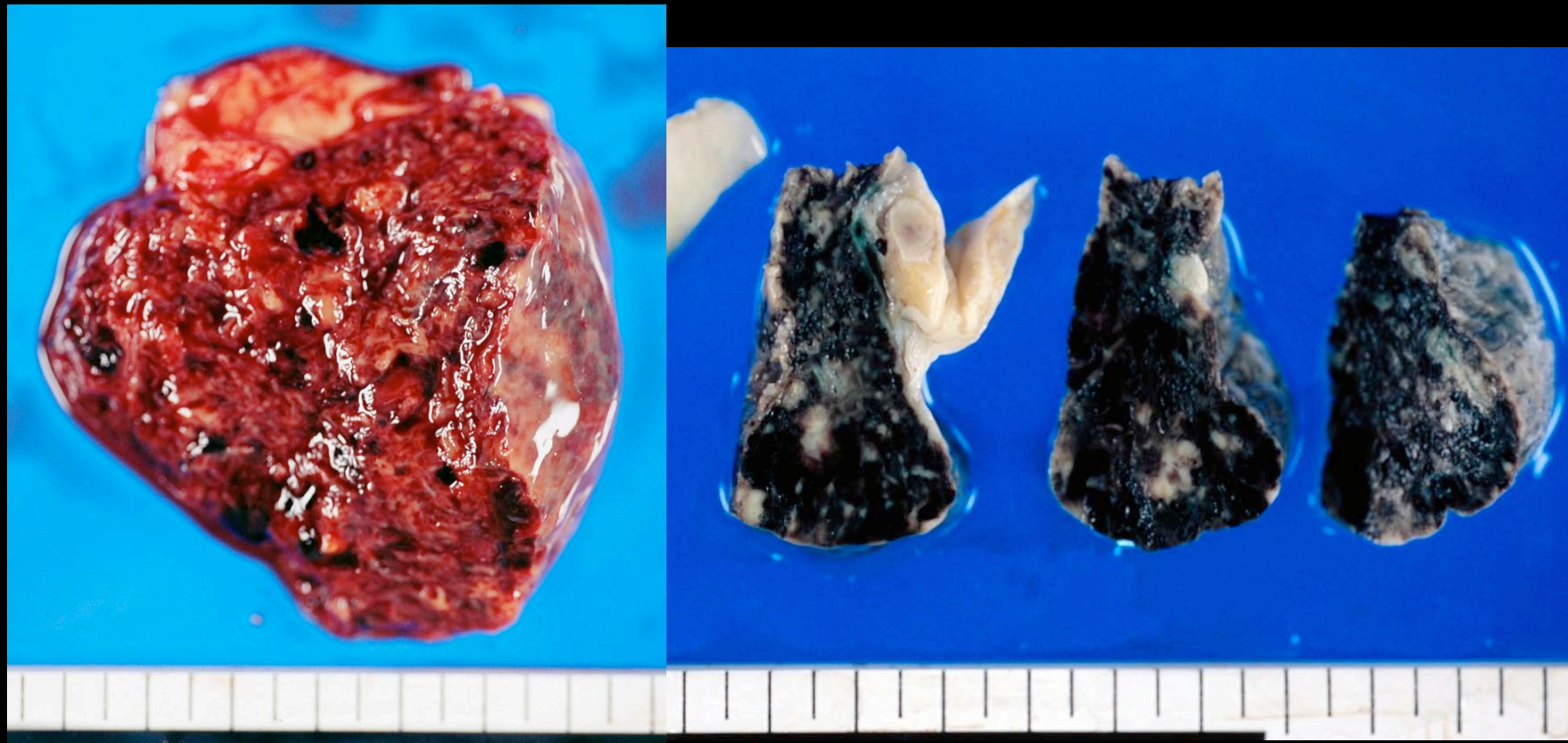


組織像 (HE x10)

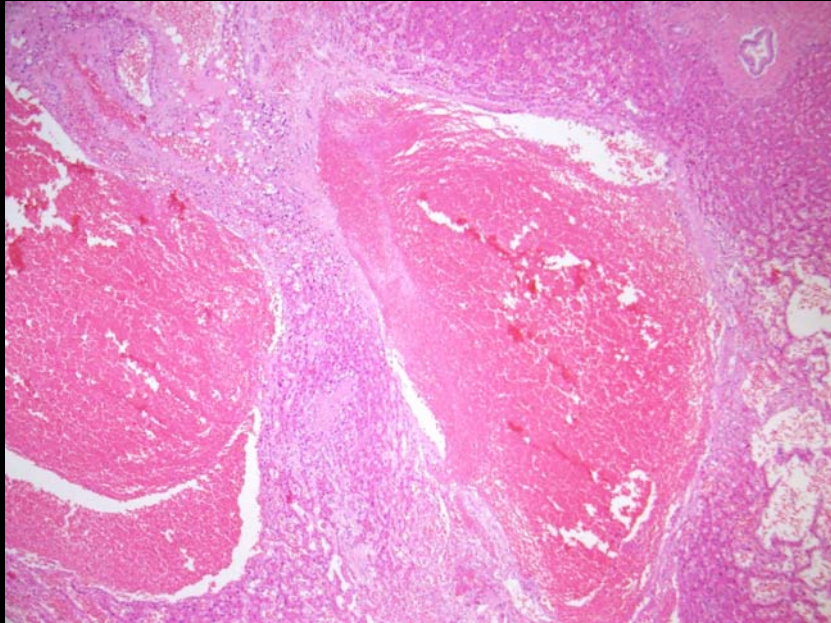


Gross pathologic appearance

Multiple, irregularly shaped blood-filled hepatic cavities. The lesions typically involve the entire liver.



Microscopic examination



CT
NE

Early

Delayed



