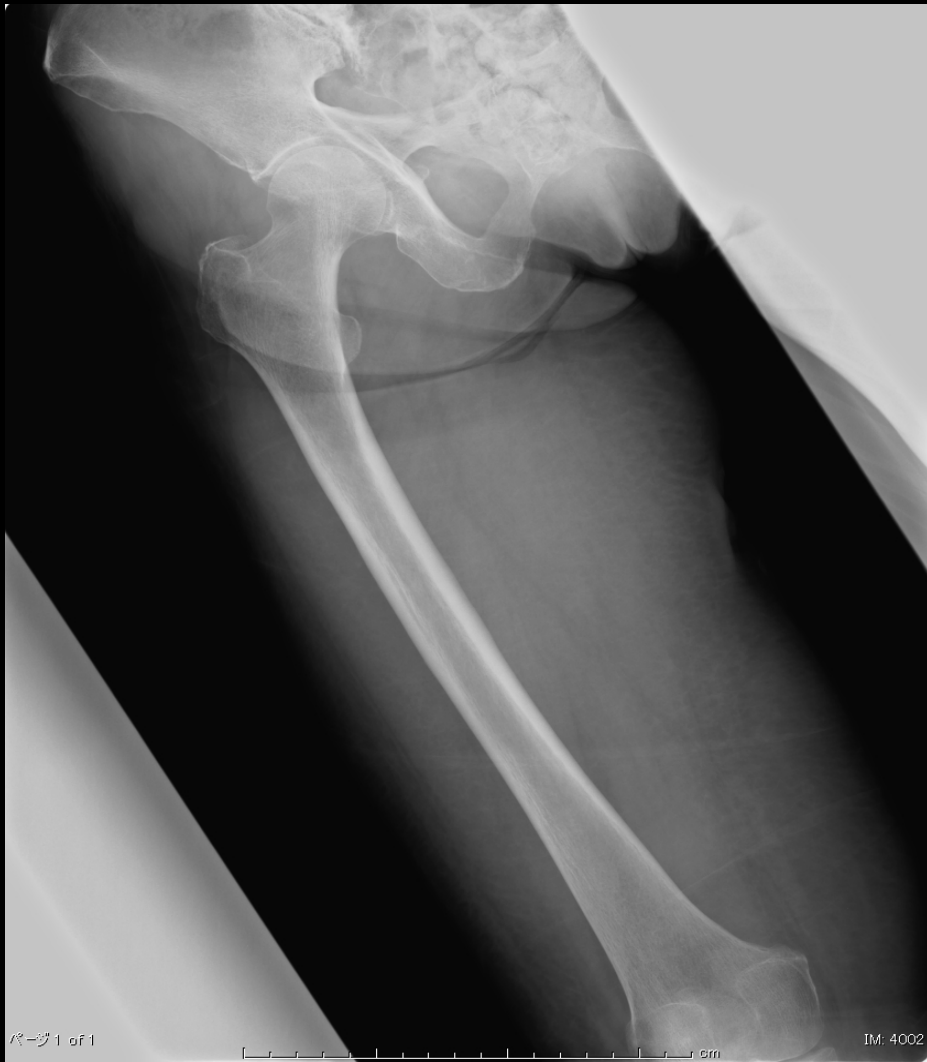
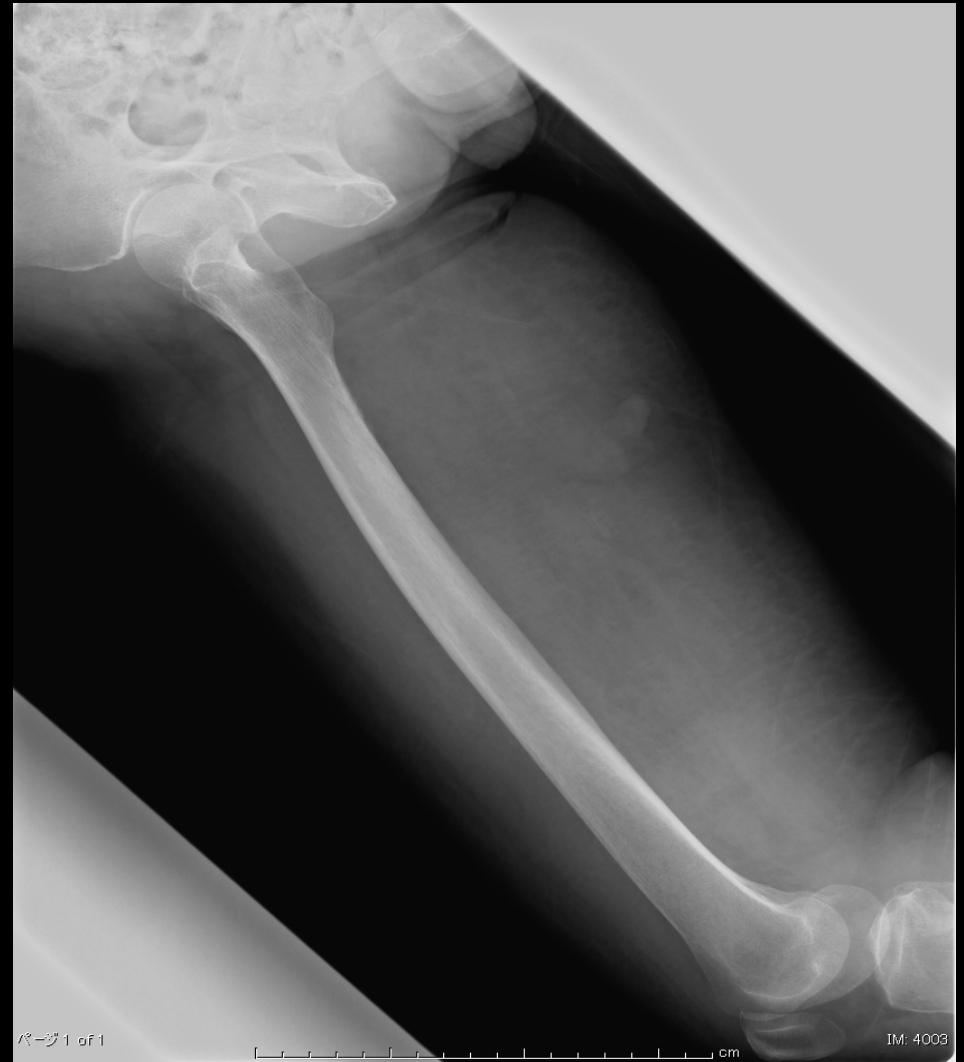
# 【右大腿骨単純写真】

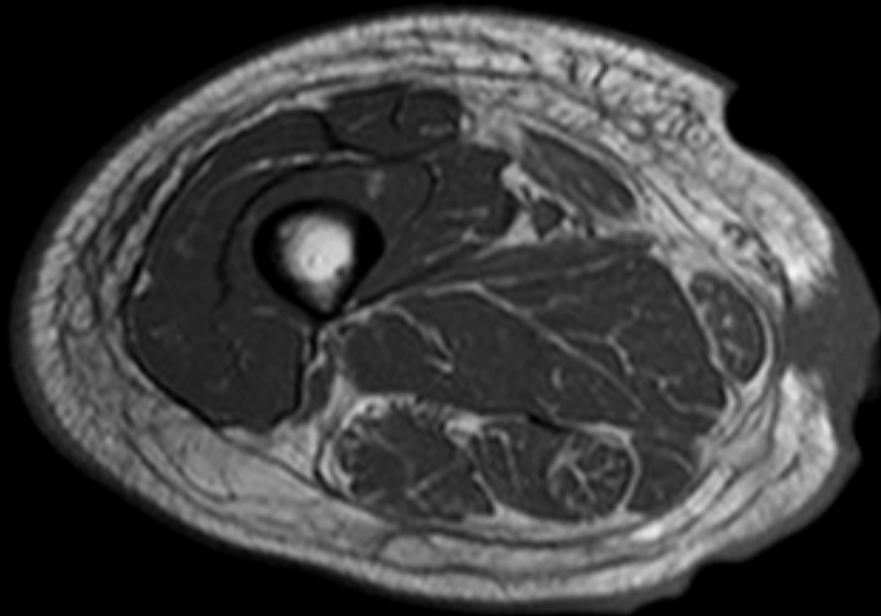


正面像

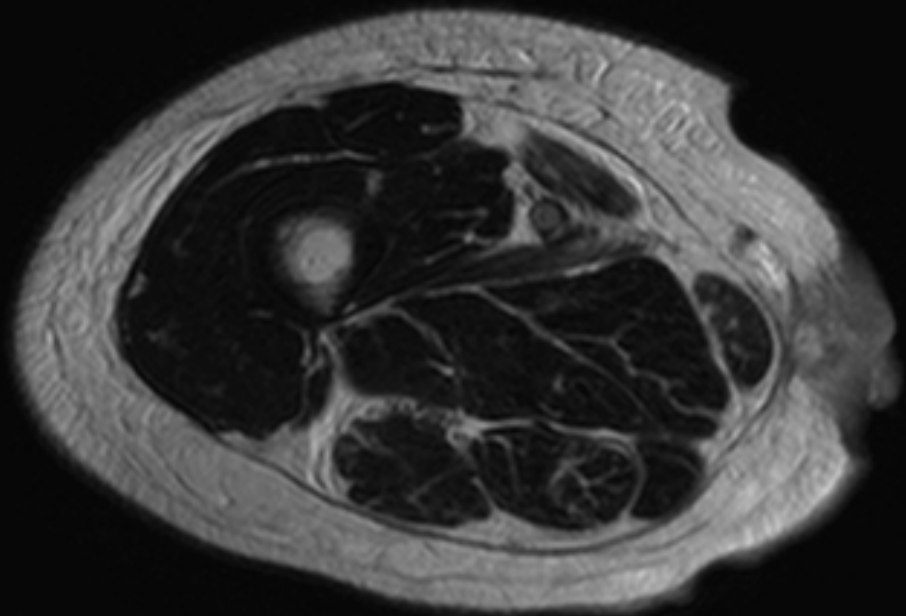


側面像

# 【右大腿部MRI】

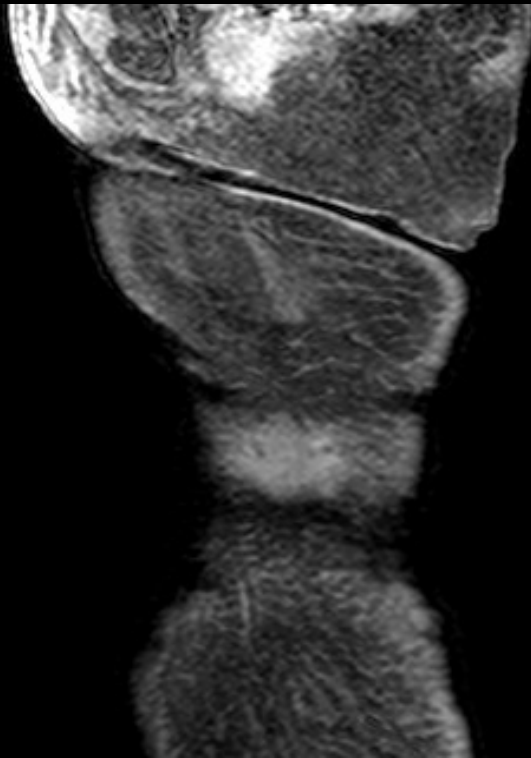

T1WI

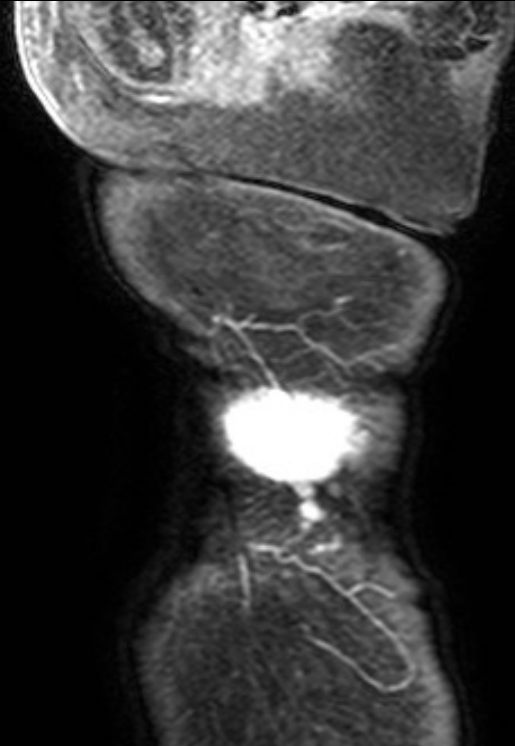

T2WI

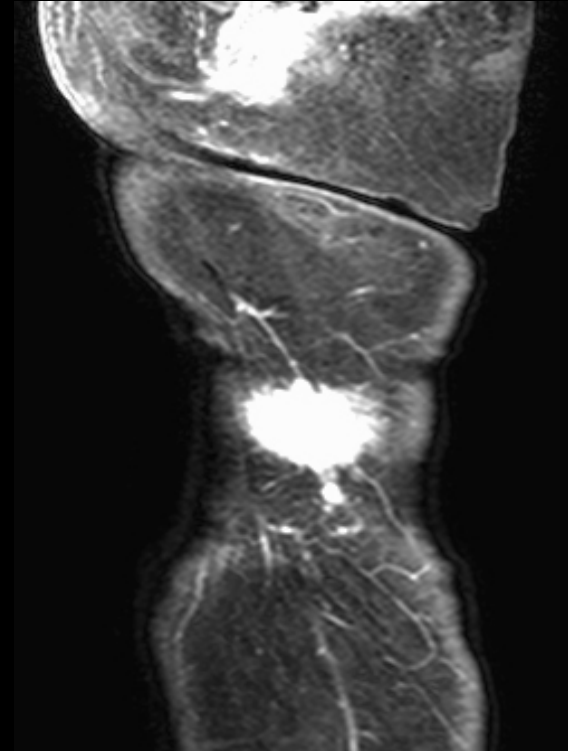
# 【Dynamic sagittal】



pre

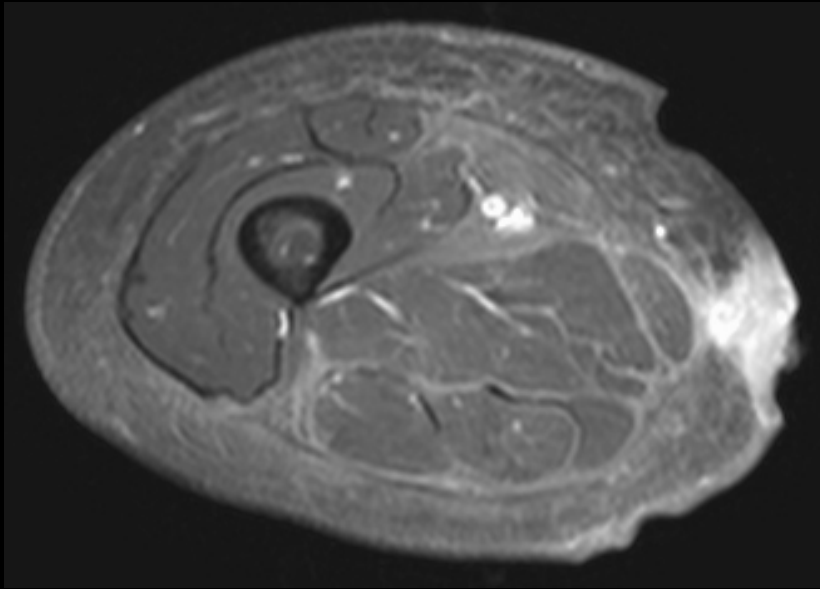


arterial phase

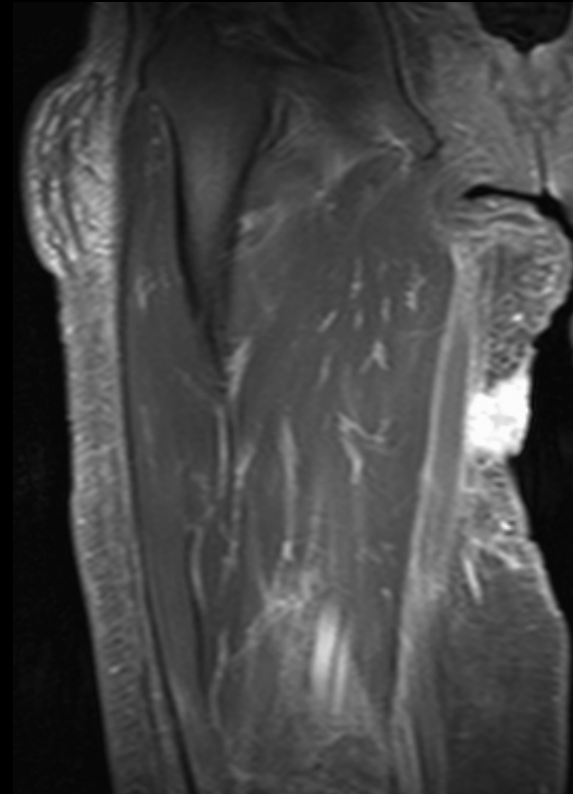


delayed phase

**【Delayed phase】**



**axial**



**coronal**