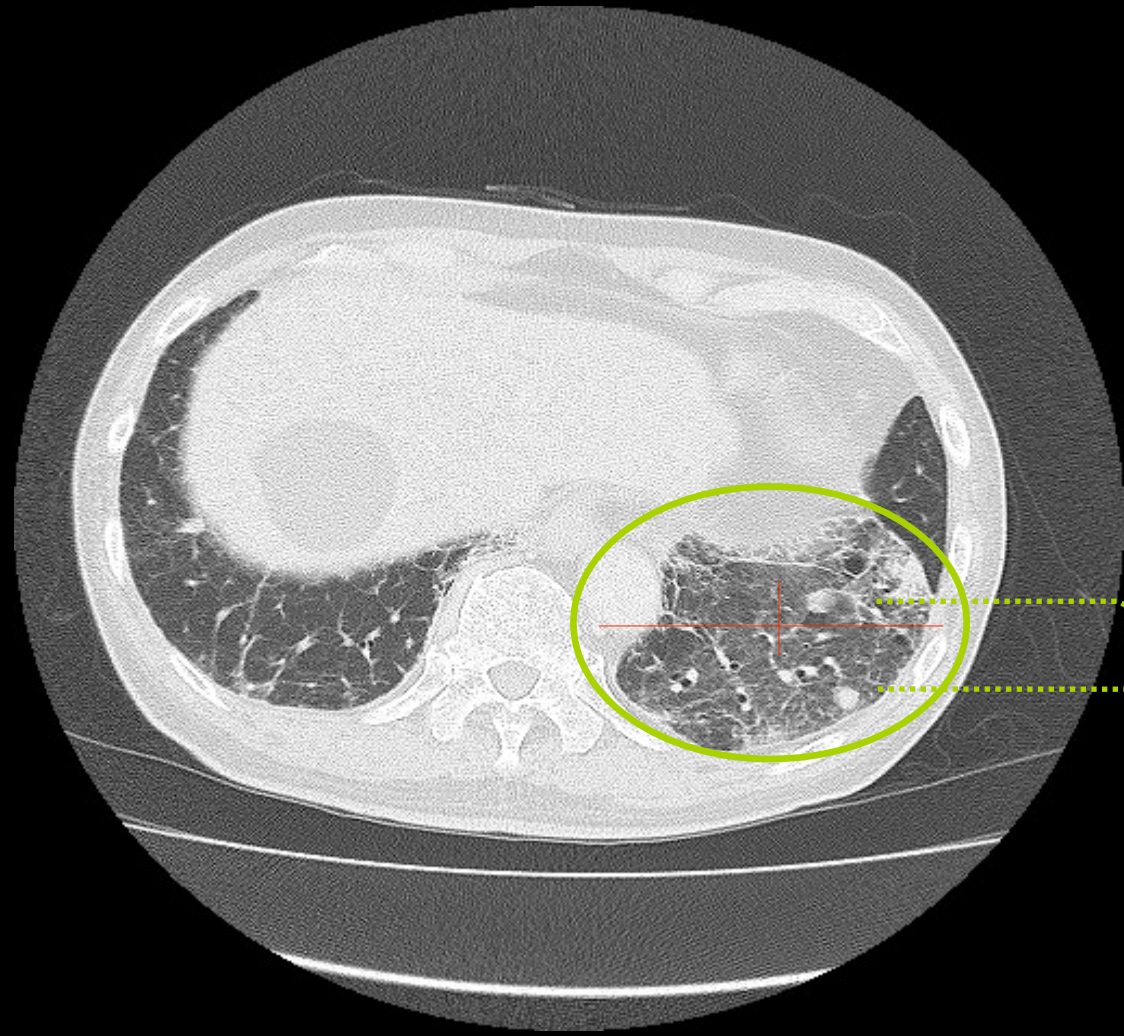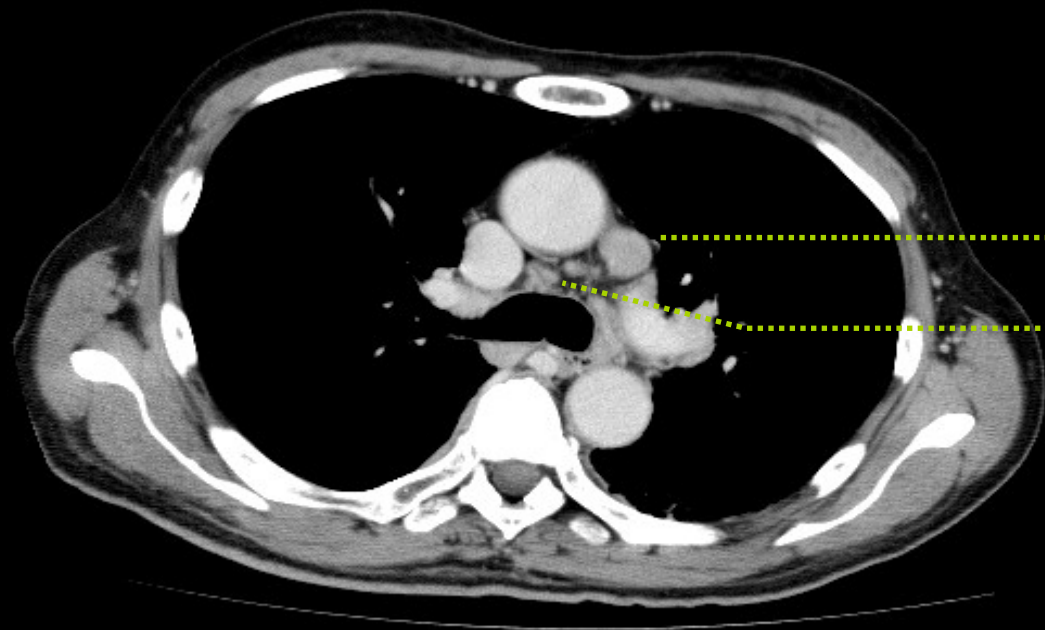
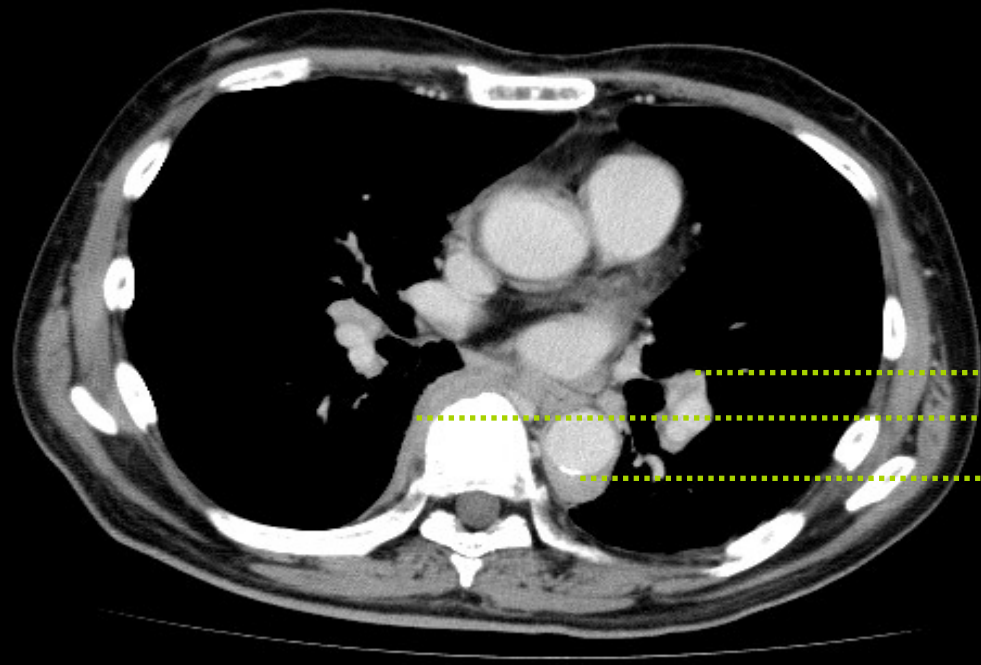




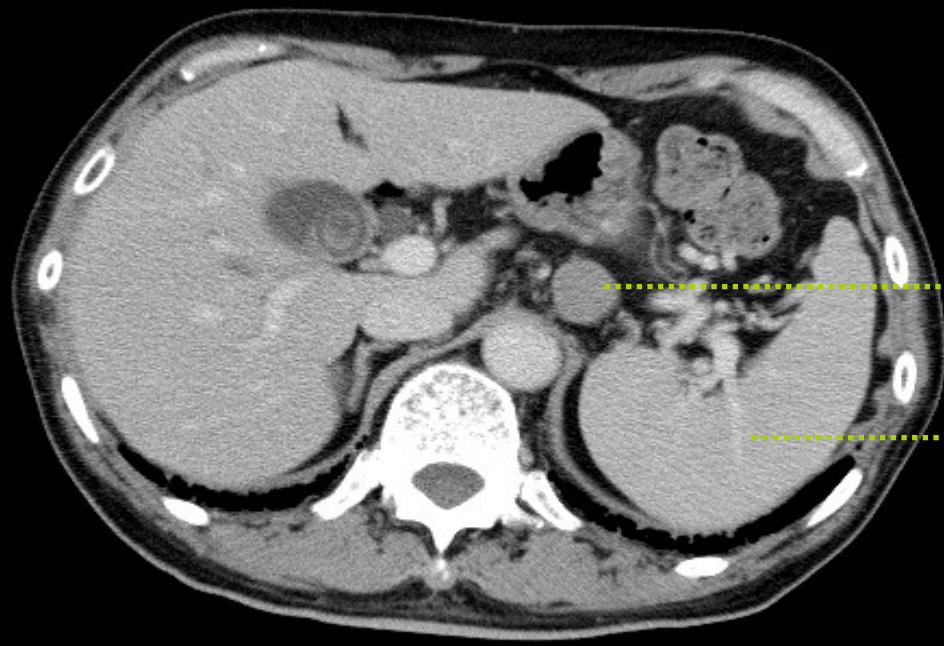
肺野
結節影
索状影



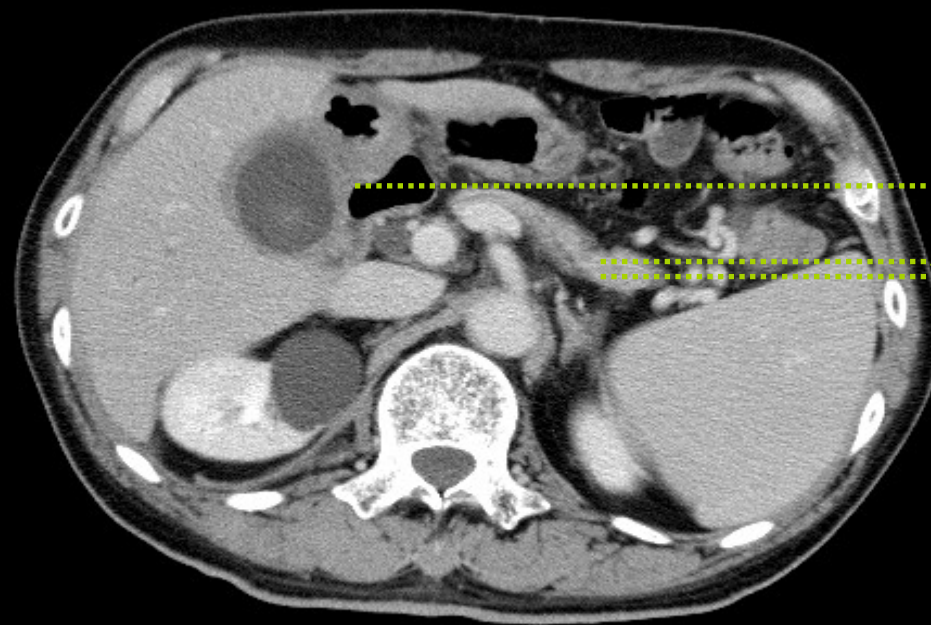
縱隔LN
腫脹



肺門LN腫脹
椎体・Ao周圍
軟部陰影

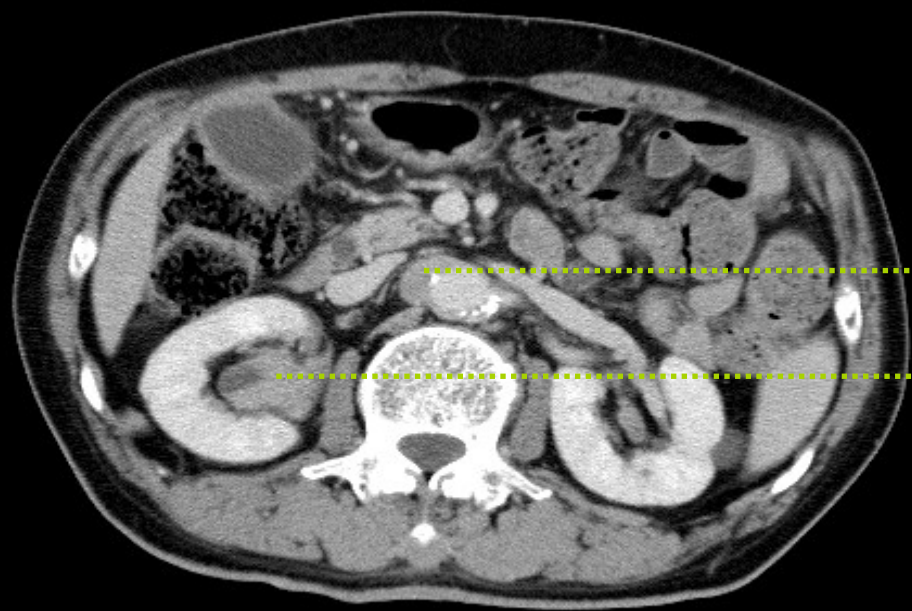

LN腫脹susp
脾腫



胆囊壁肥厚

膽邊緣平滑化
周圍低吸收域



腹部大動脈
周圍軟部影
腎門部軟部影