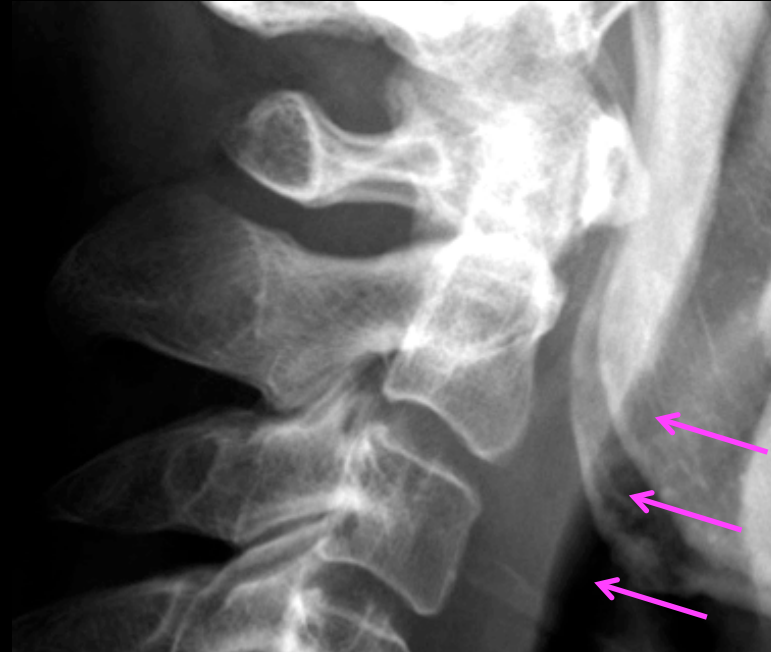
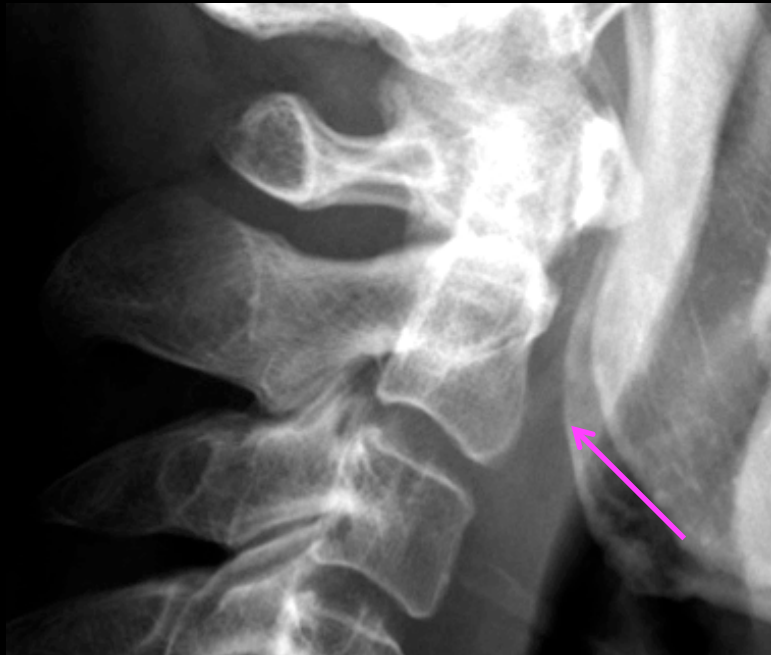
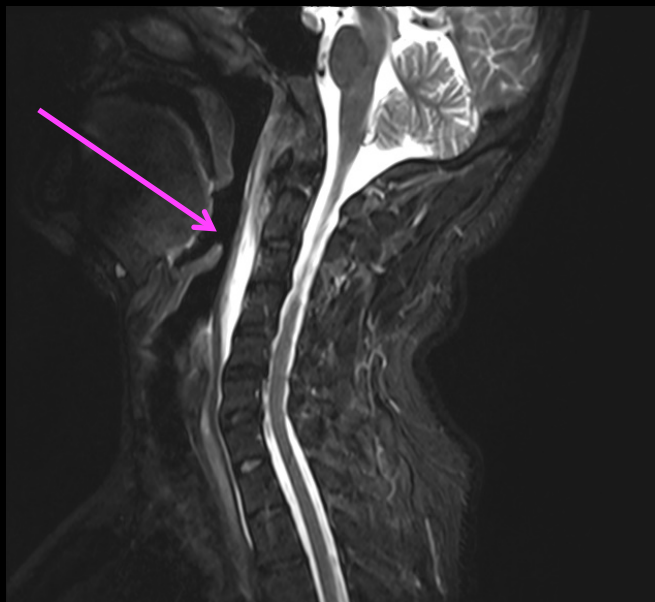


CXP



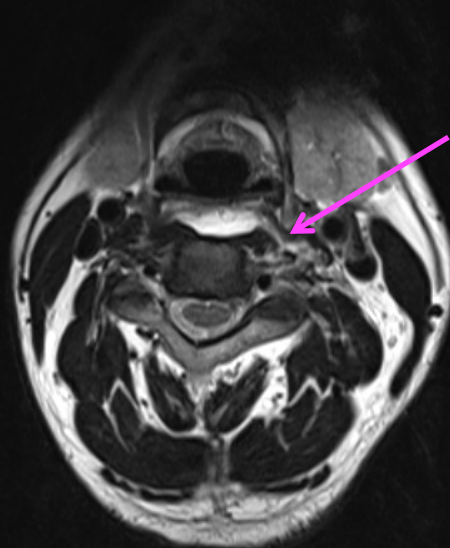
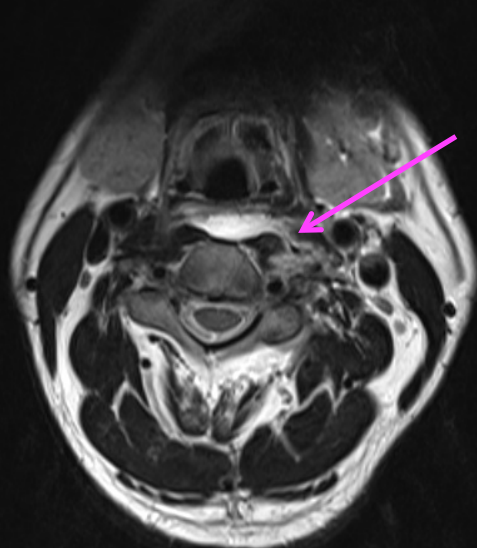
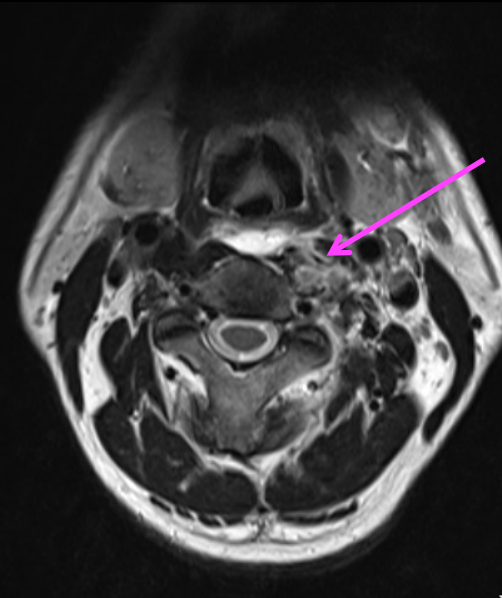
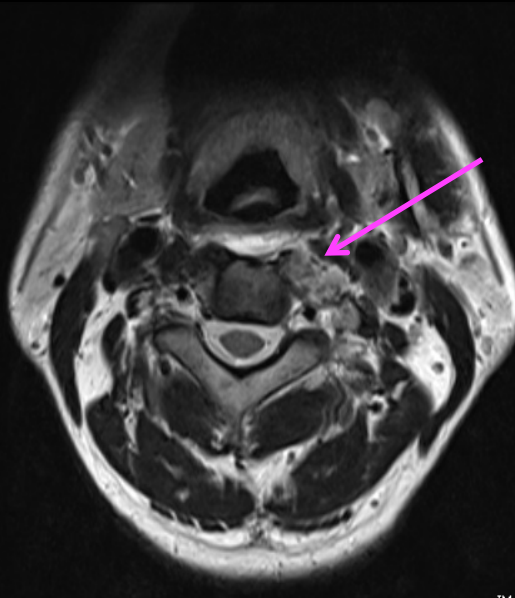
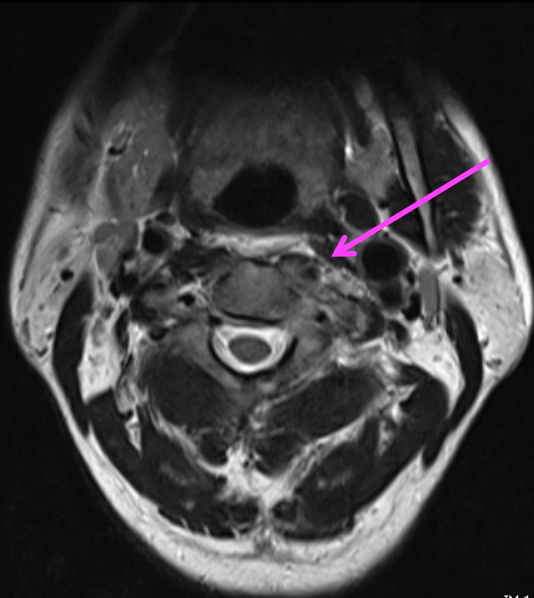
C1 1-10mm
C2 < 7mm



MRI assessment of the pre-vertebral soft tissues in acute cervical spine trauma. Br J Radiol. 1999;72:818-23.

STIR2

T2WI



CT(非提供)

