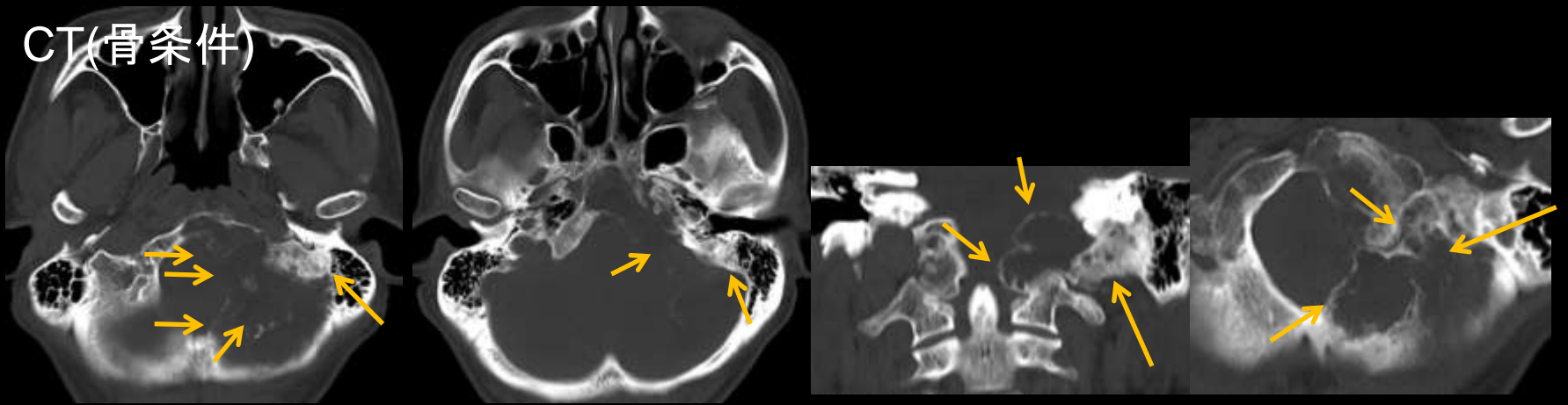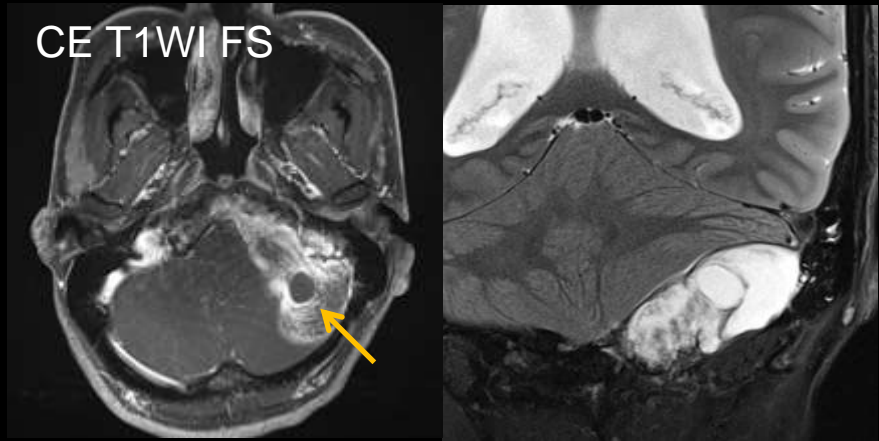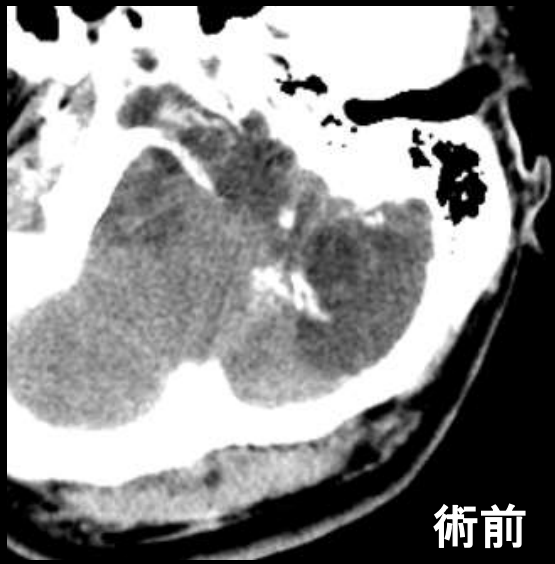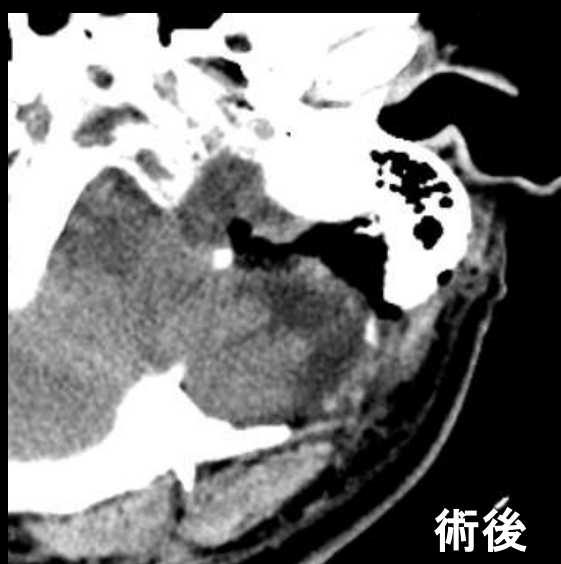
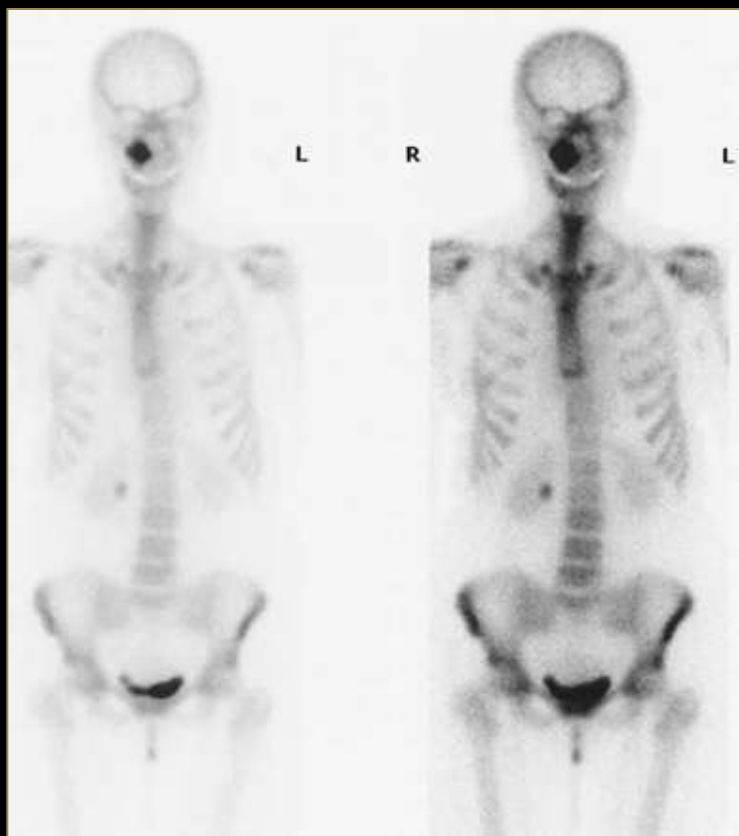


術前

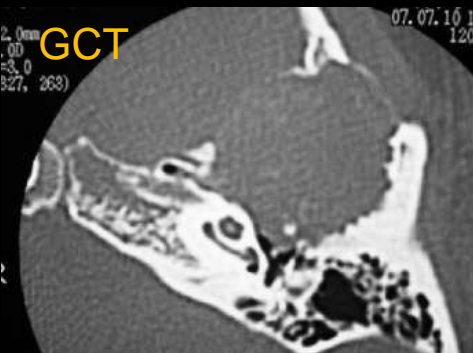
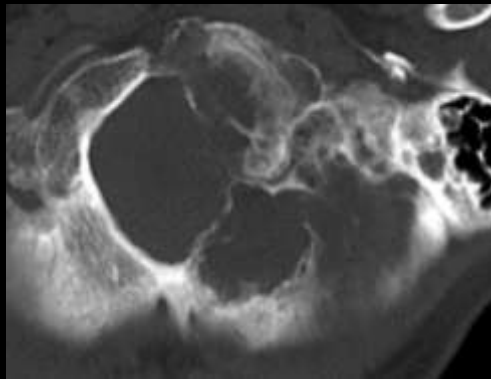
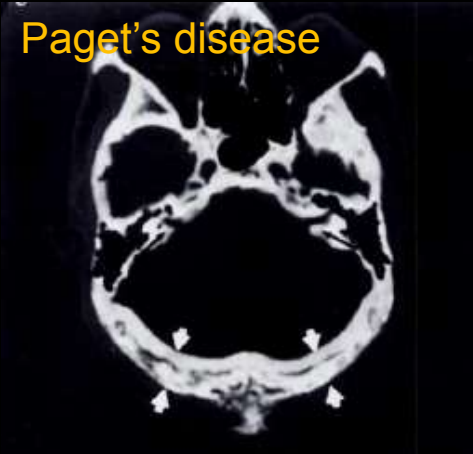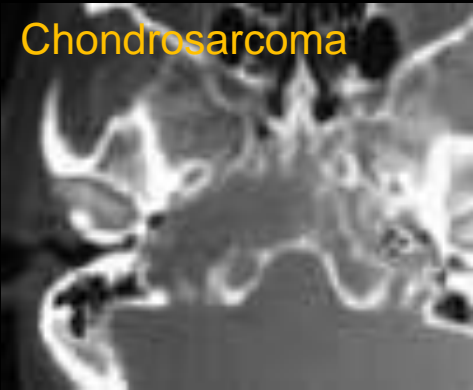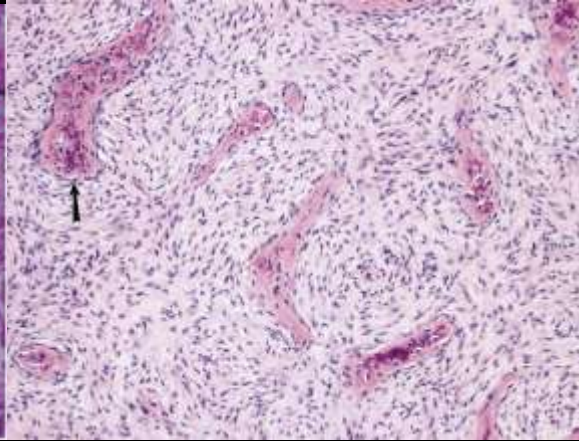
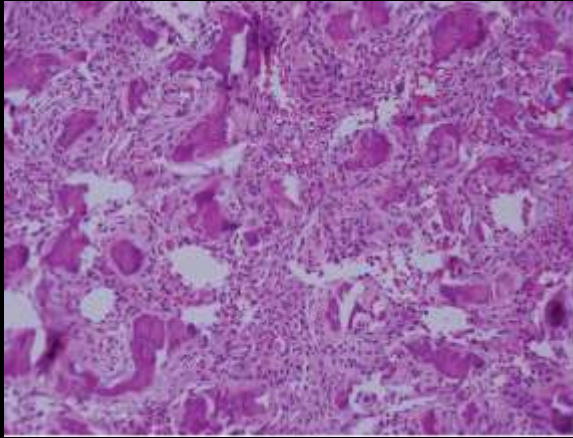


術後



sclerotic

cystic(active)



単純CTのthin sliceを詳細に観察