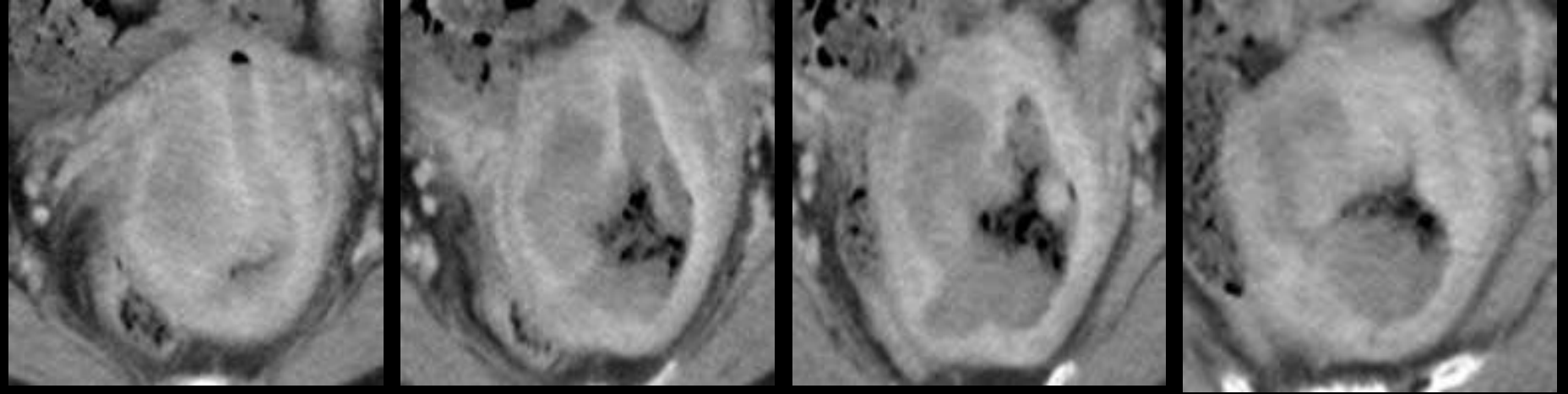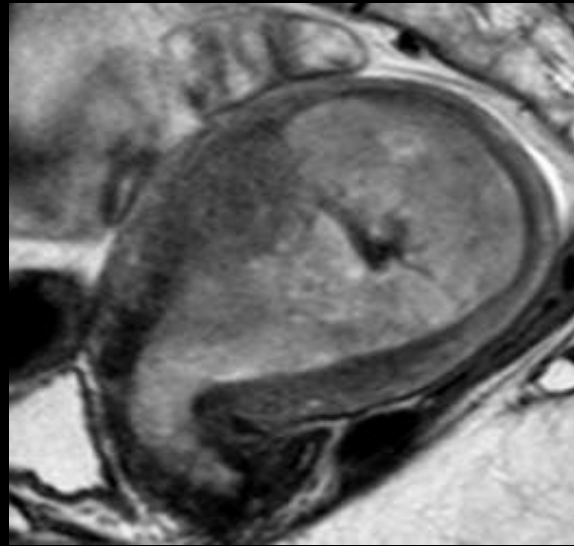
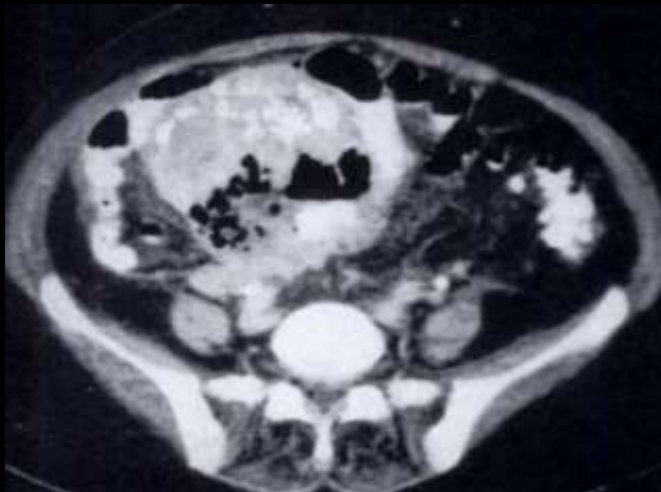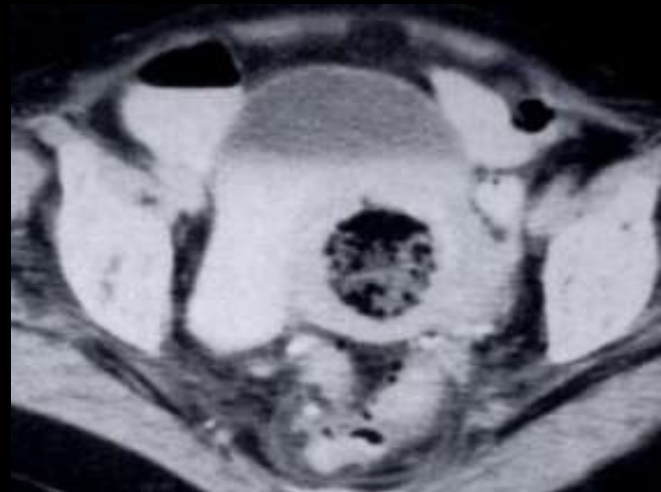


9日目 造影

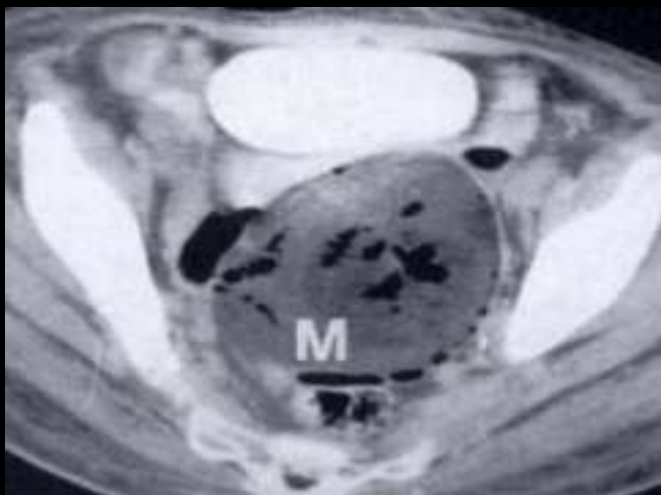



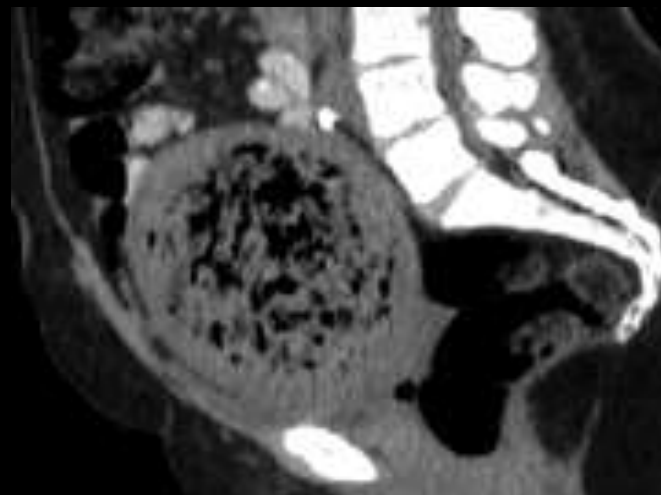
**superinfected leiomyoma, sepsis**



**uterine cancer, Clostridium perfringens**



**superinfected dermoid**



**pyomyoma, bilateral UAE**