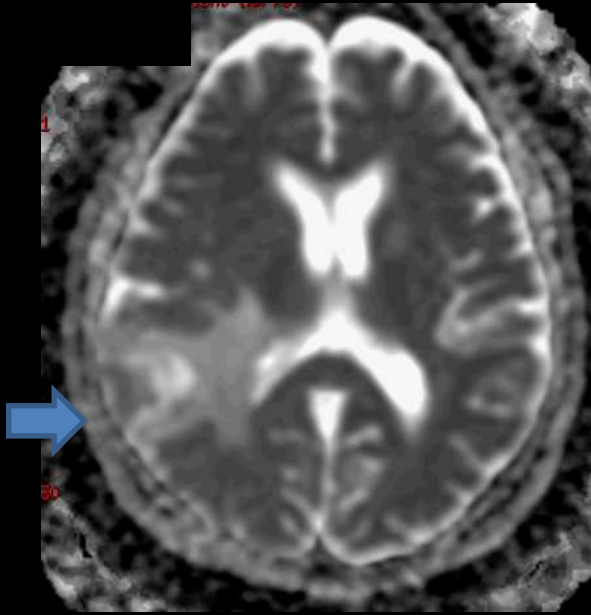
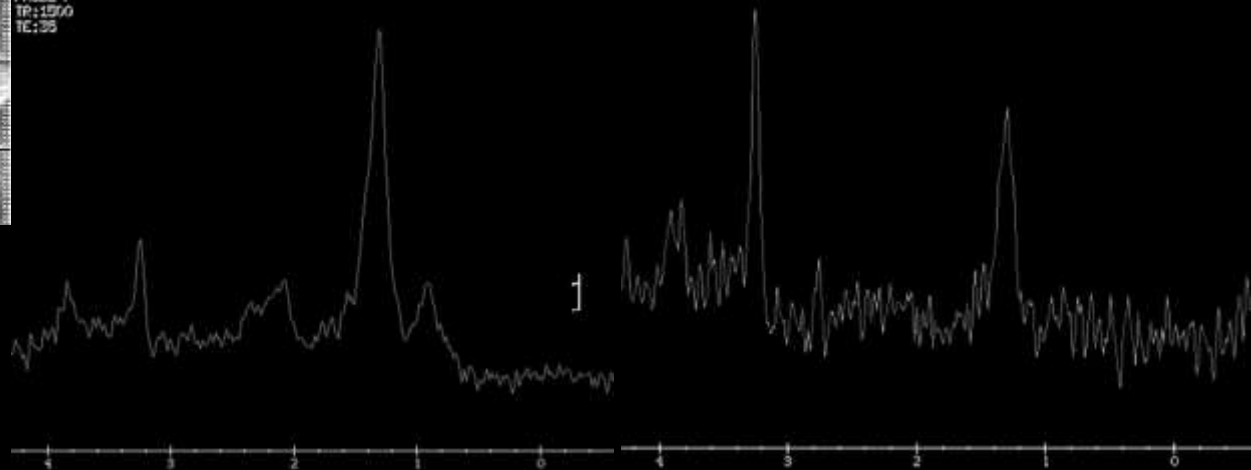


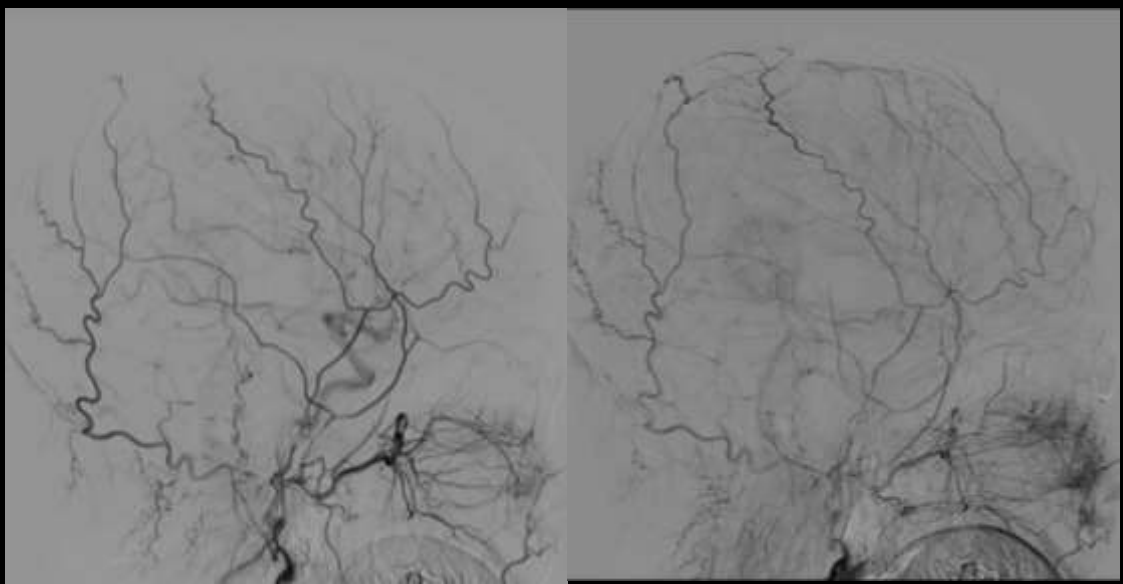
拡散強調像 ADC



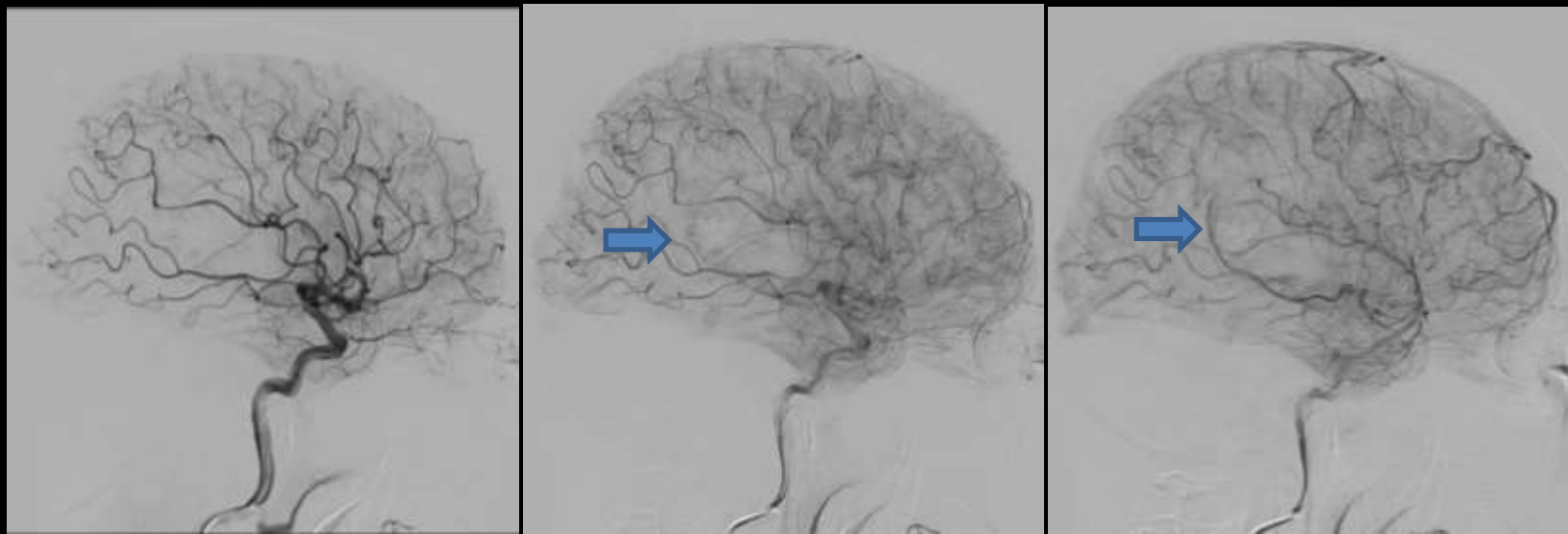
Single voxel proton MRS PRESS enhanced area
Short TE (TR/TE 1500/35ms) Intermediate TE (1500/144ms)



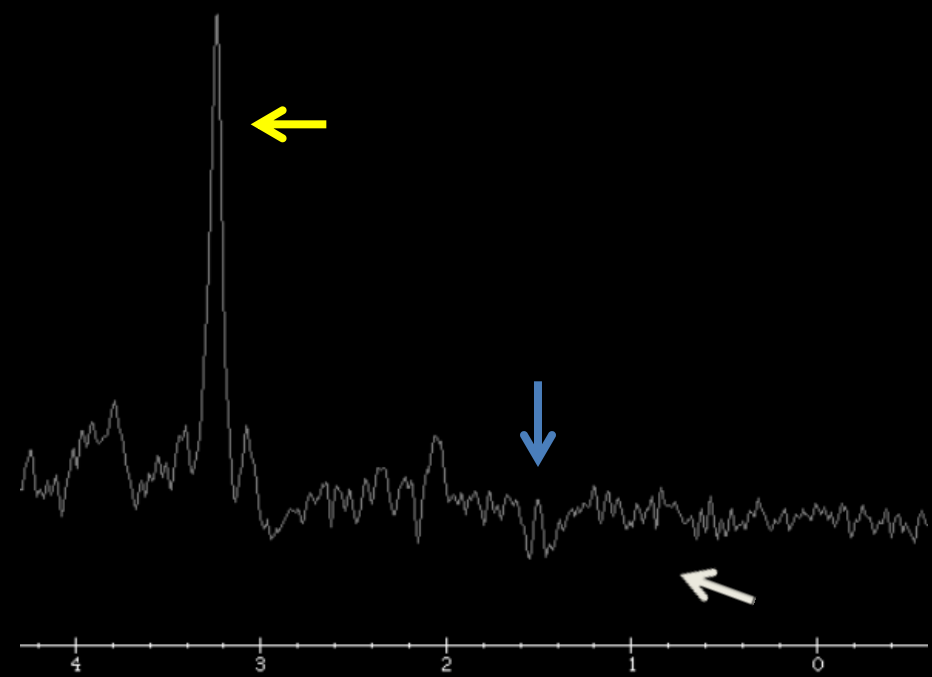
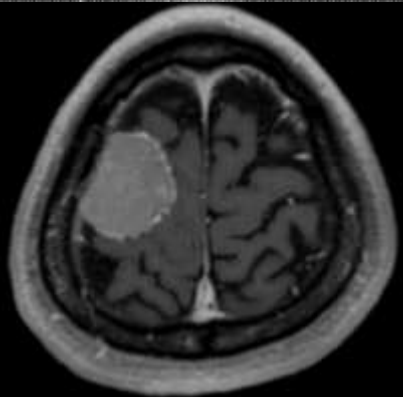
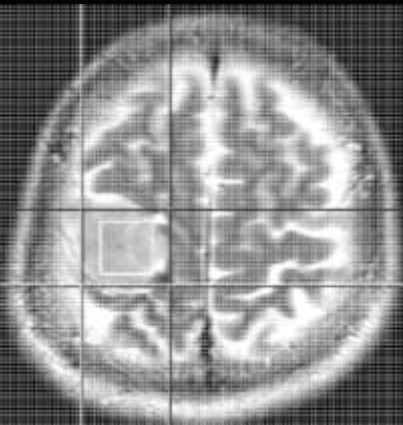
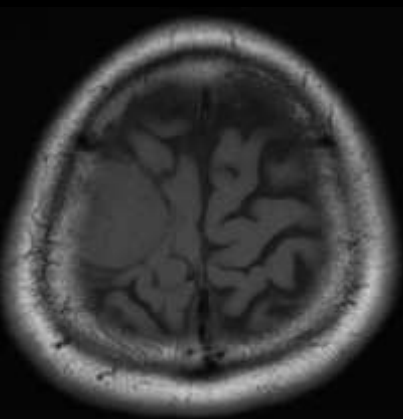
右外頸動脈造影 側面像



右內頸動脈造影 側面像

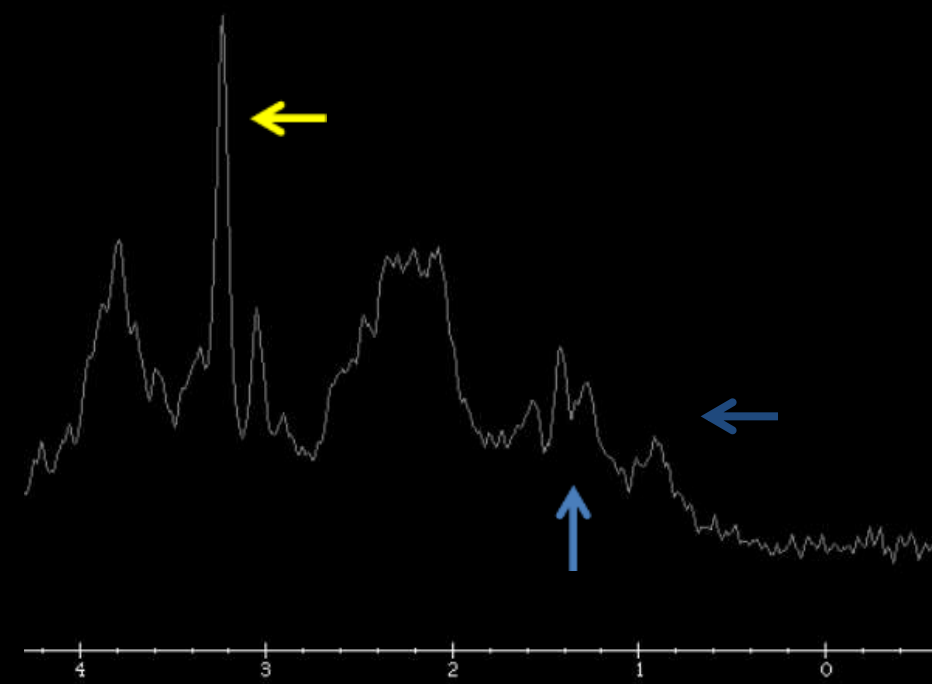


MRS 参考画像



比較的典型的な
髄膜腫のMRS
所見 当院症例
SV PRESS法

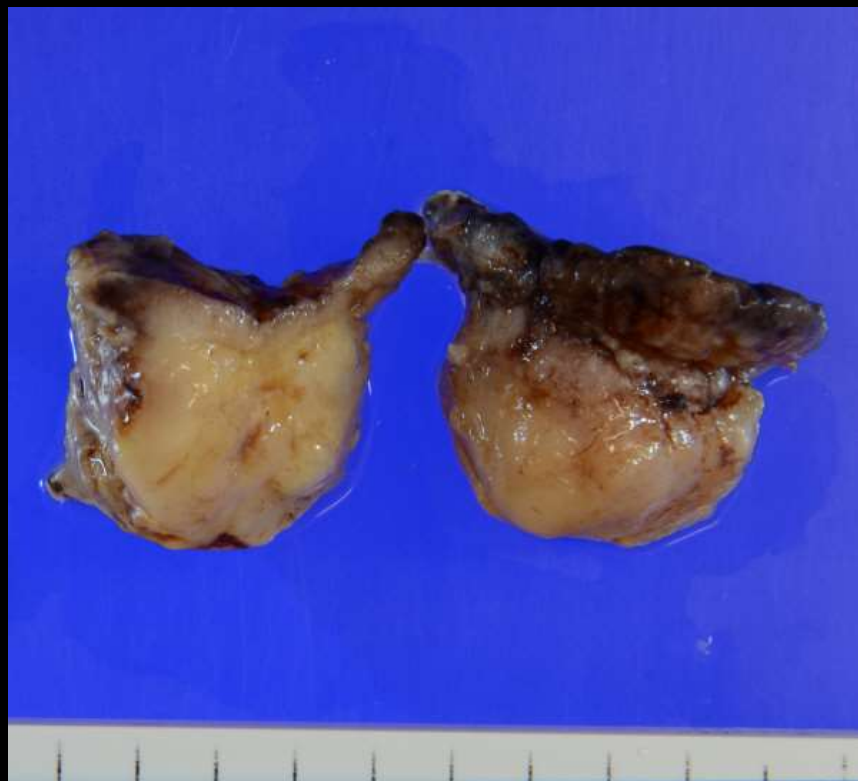上段
intermediate TE
TR/TE1500/144ms



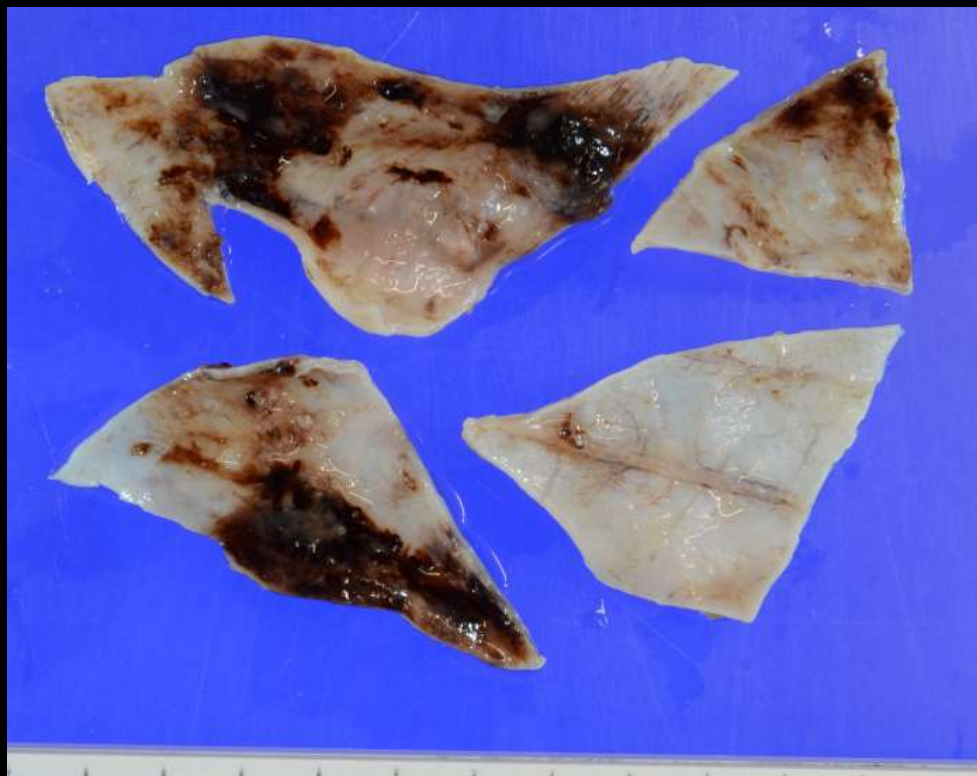下段
short TE
1500/35ms

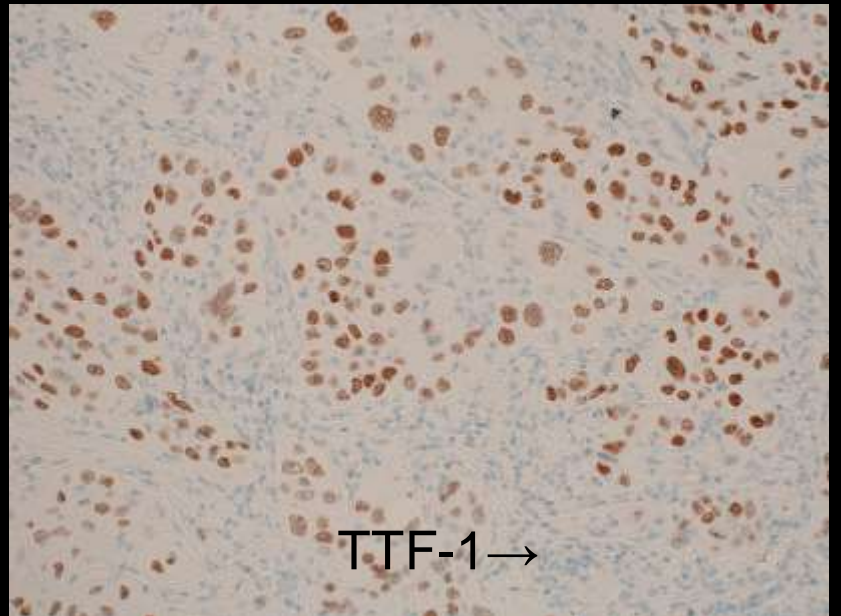
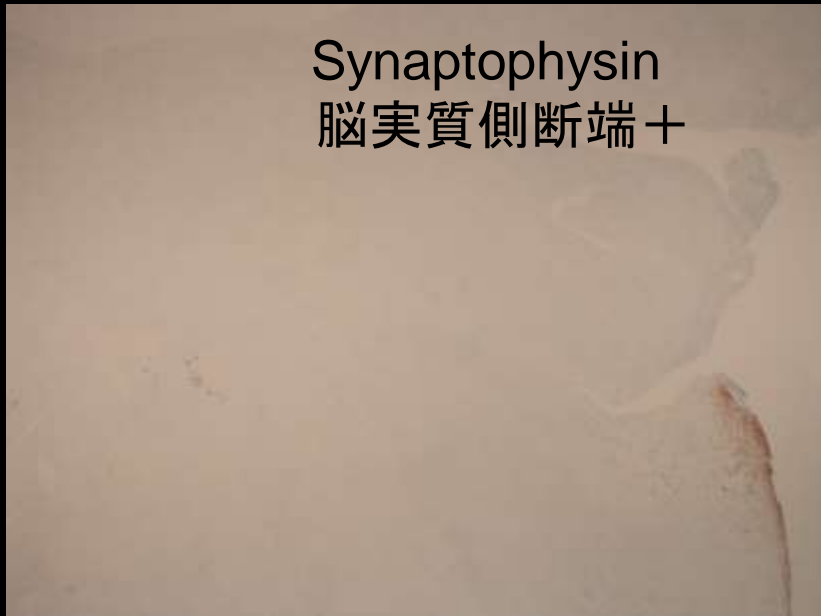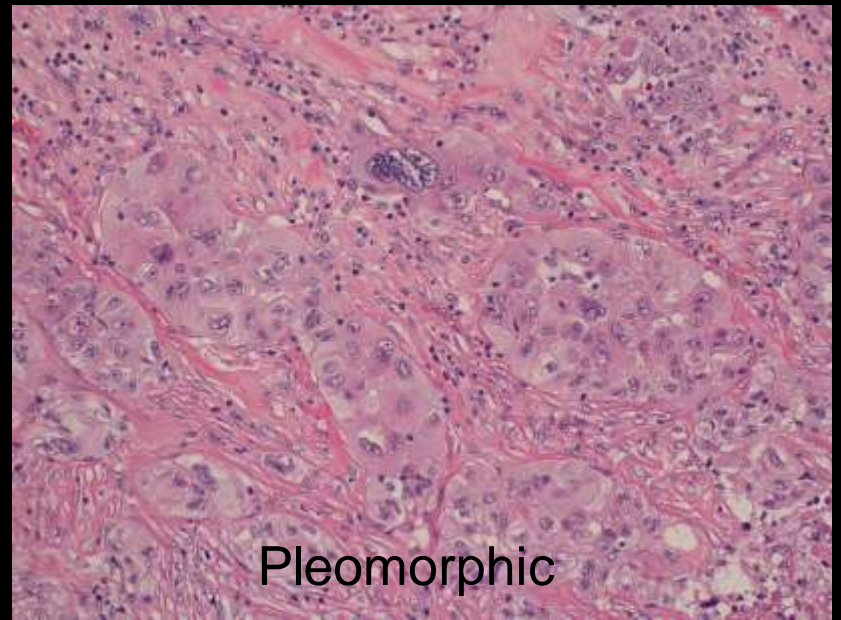
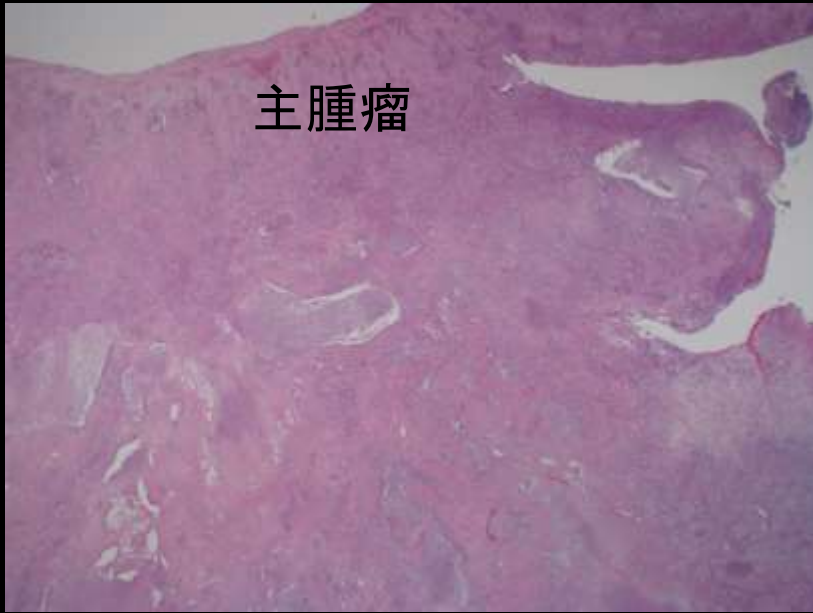
コリンピークの上昇:黄
→
アラニンピーク出現
青→
Lipid 白→

主腫瘍(上面は硬膜部)



硬膜

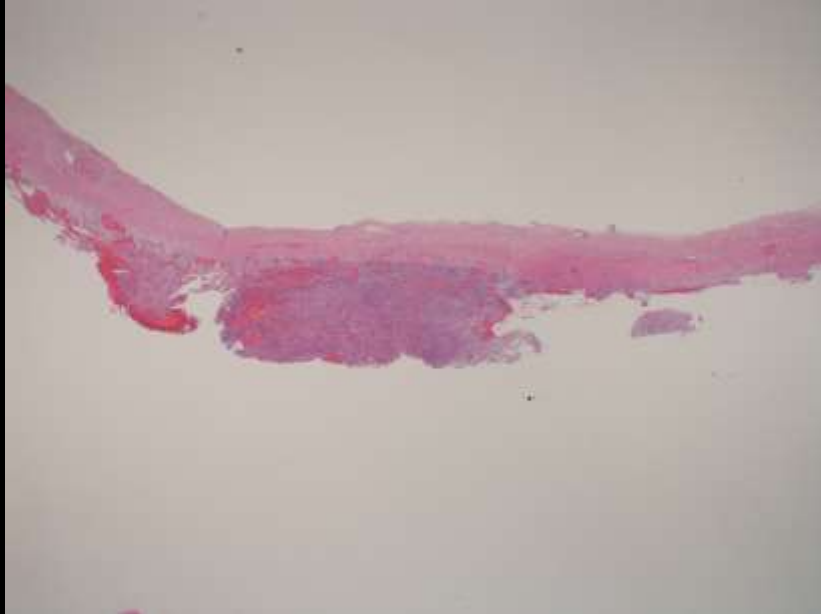



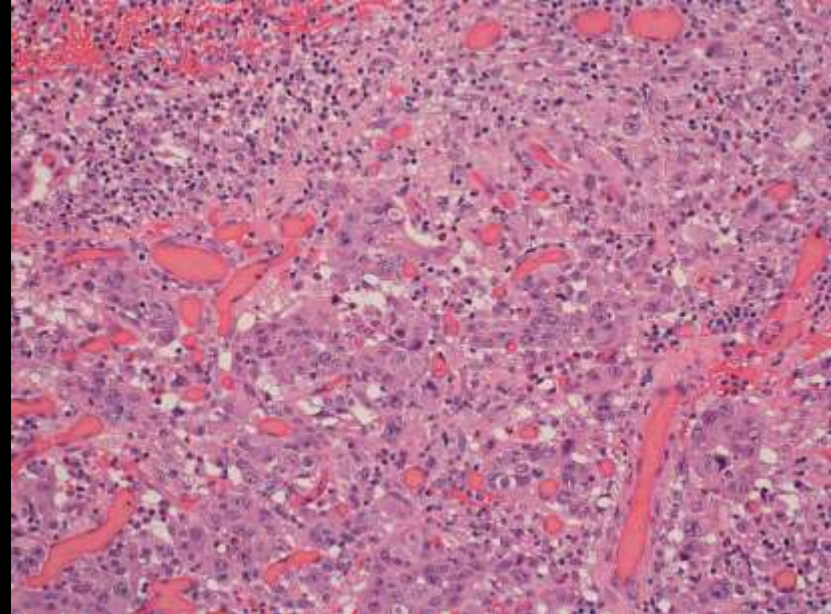
x10

x200

硬膜+壁在結節樣部



x10



x200

Pleomorphicな癌腫+炎症性肉芽組織

