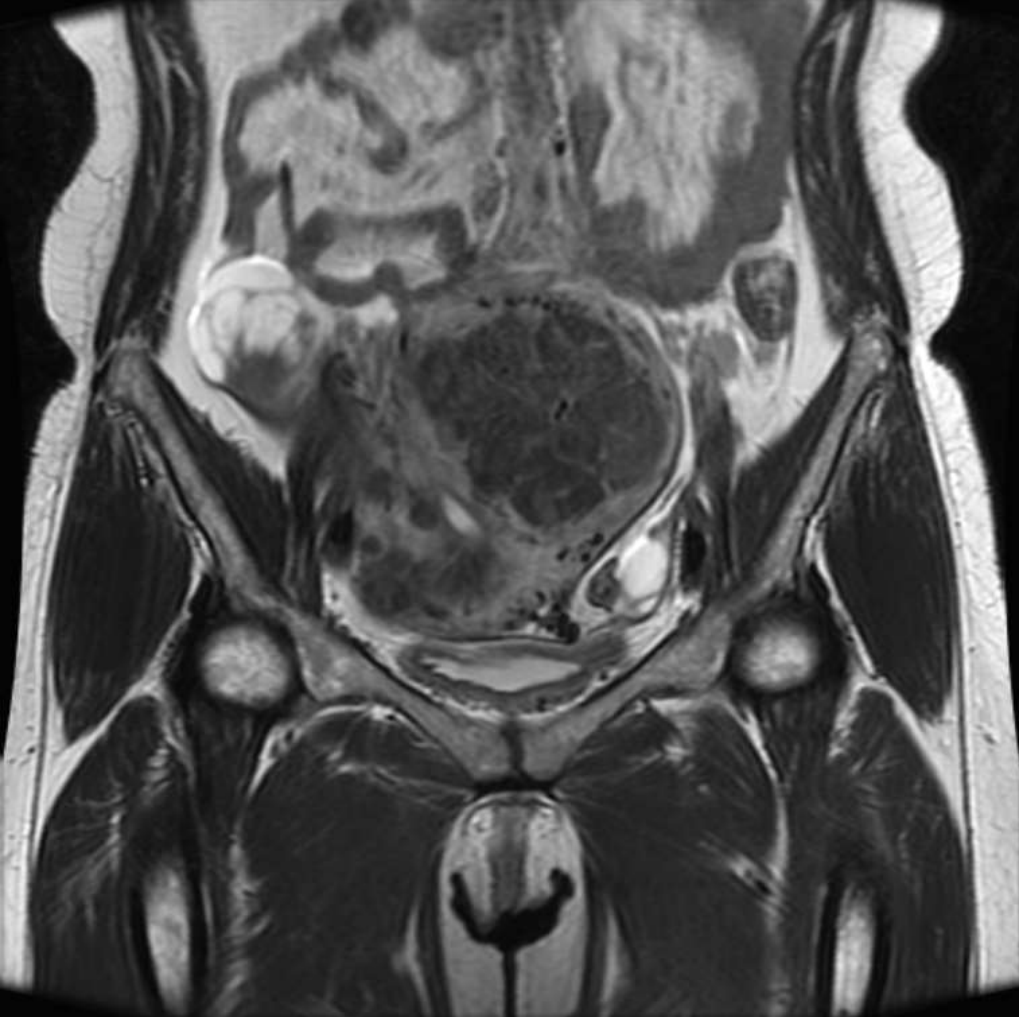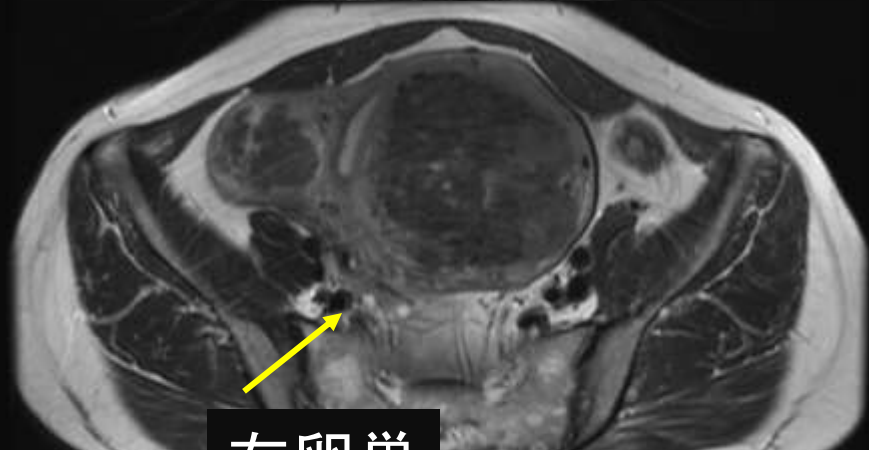
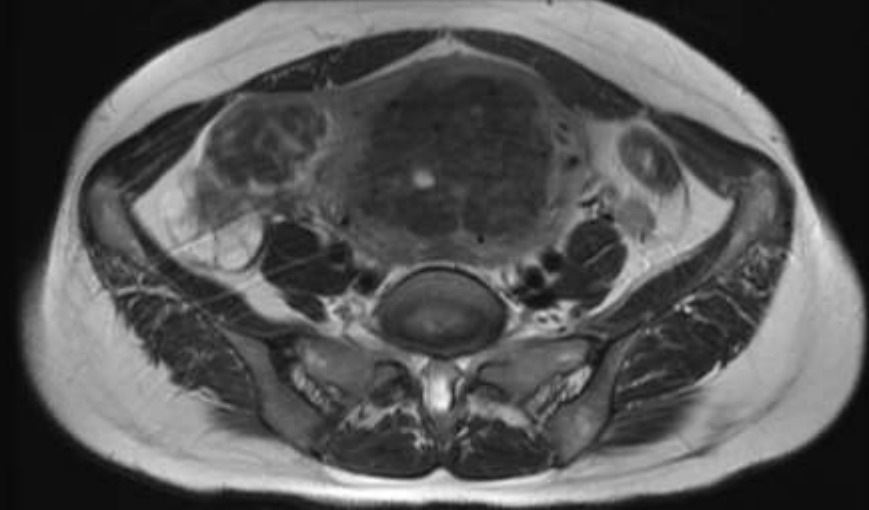
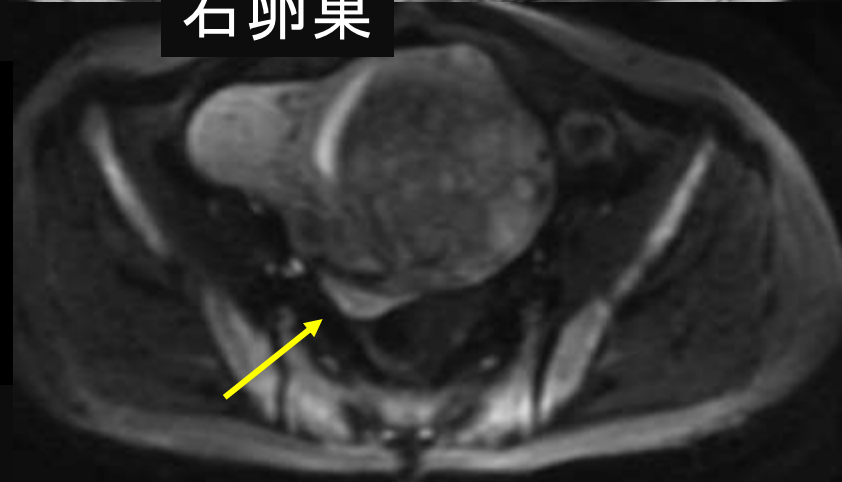


MRI:T2WI

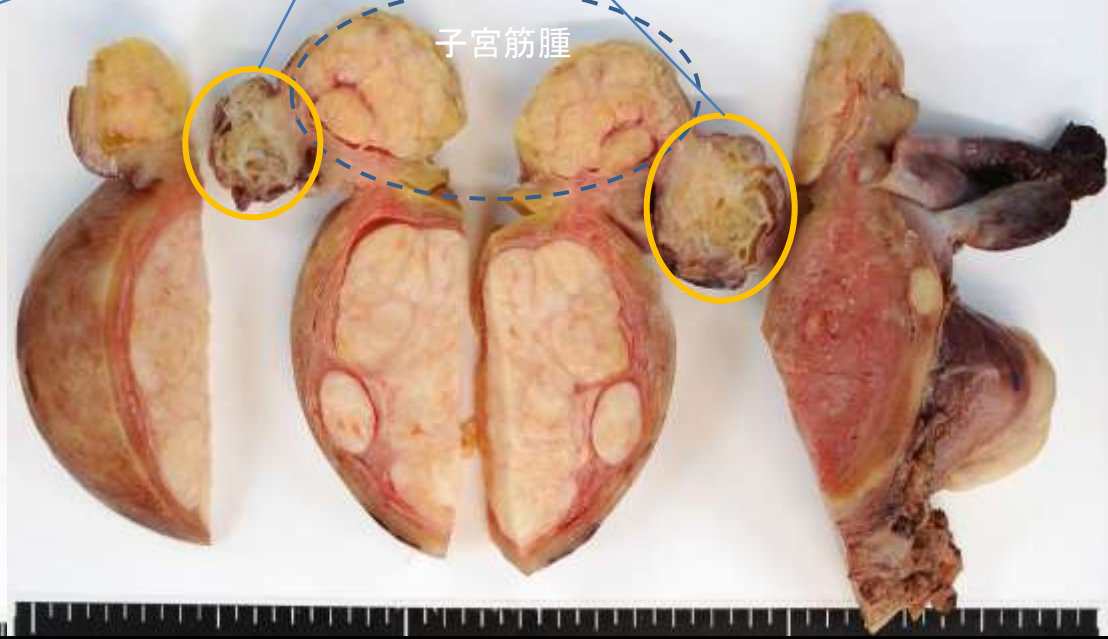
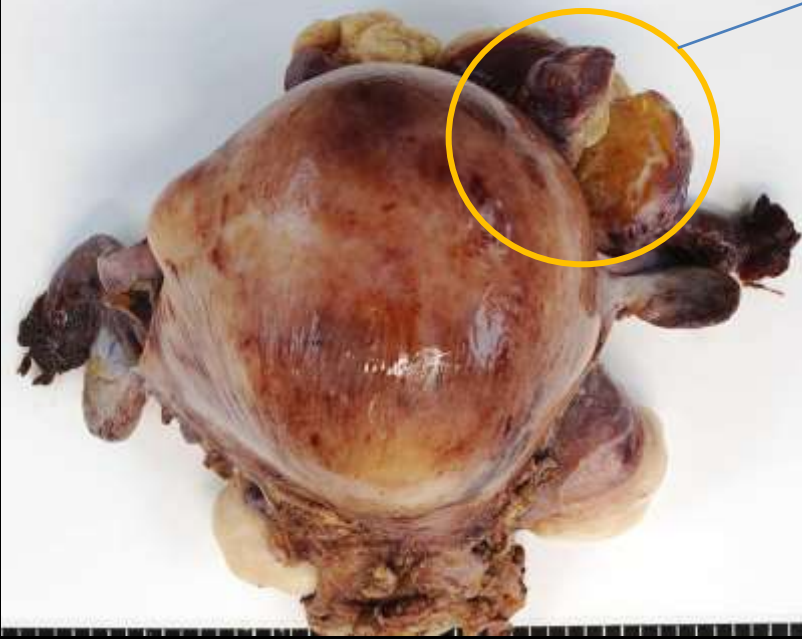

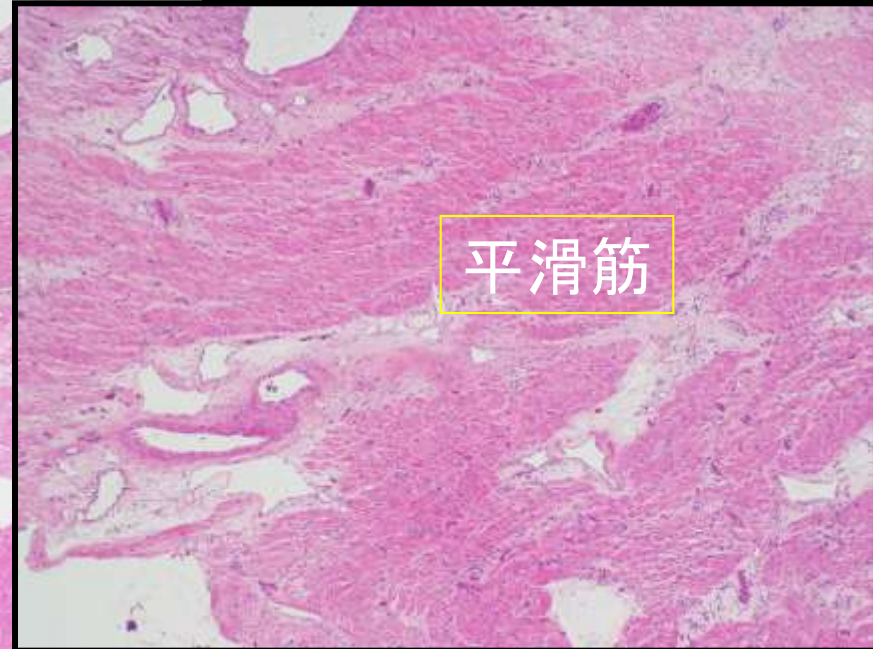
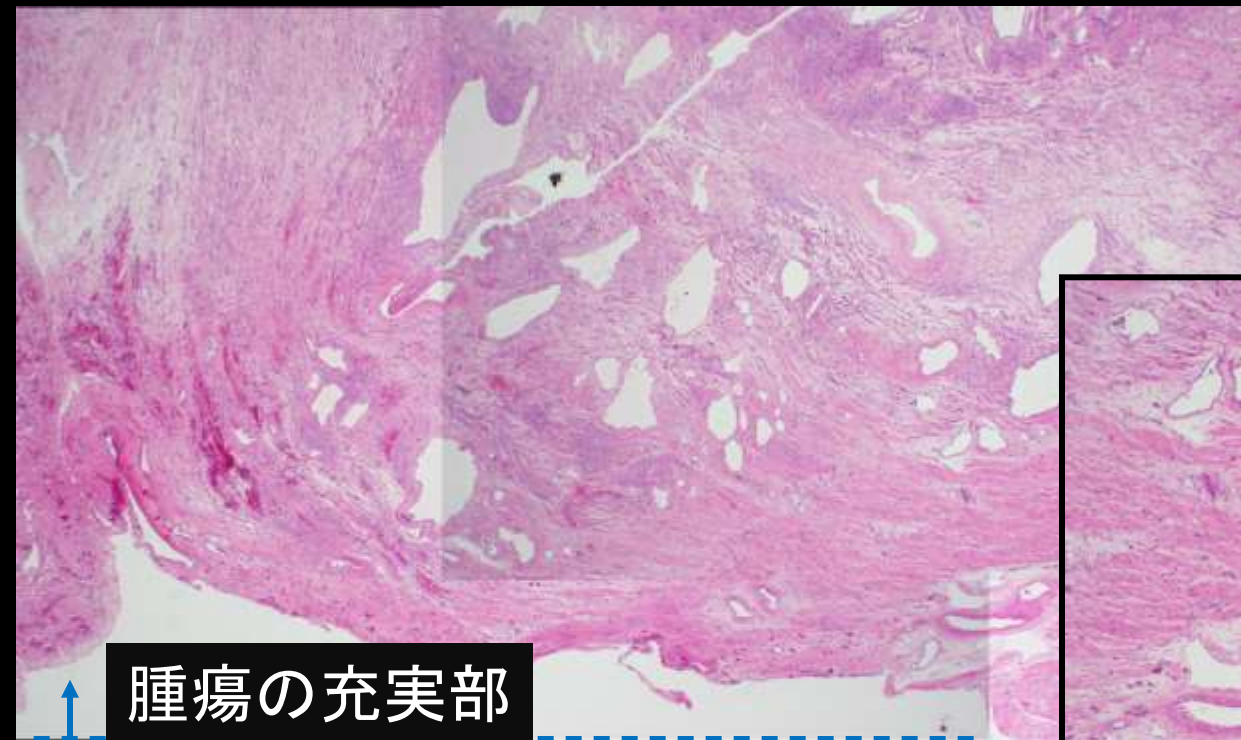
右卵巢



拡散強調像(b=1000)

多房性囊胞性腫瘤：4.0x3.0x3.7cm





平滑筋

腫瘍の充実部
正常子宮筋層

