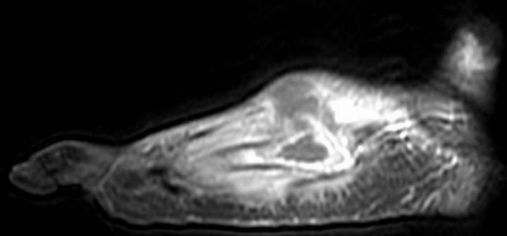
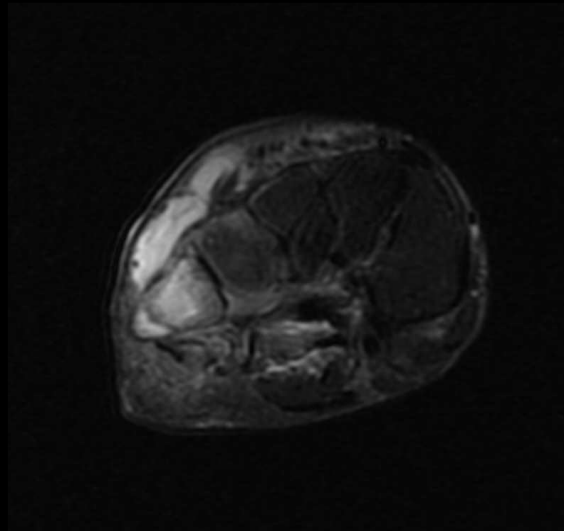


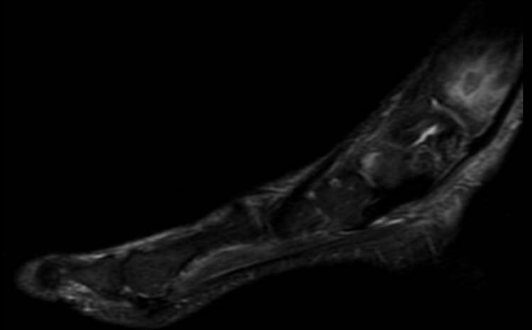
初回から1.5ヶ月後の造影MRI



fs CE T1WI sagi

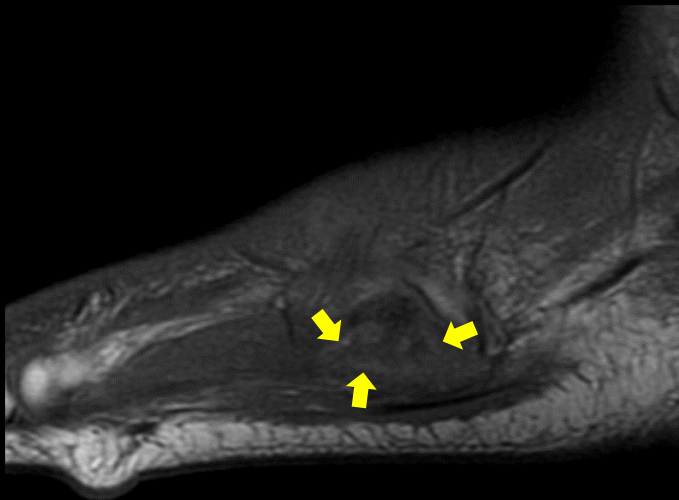


STIR cor

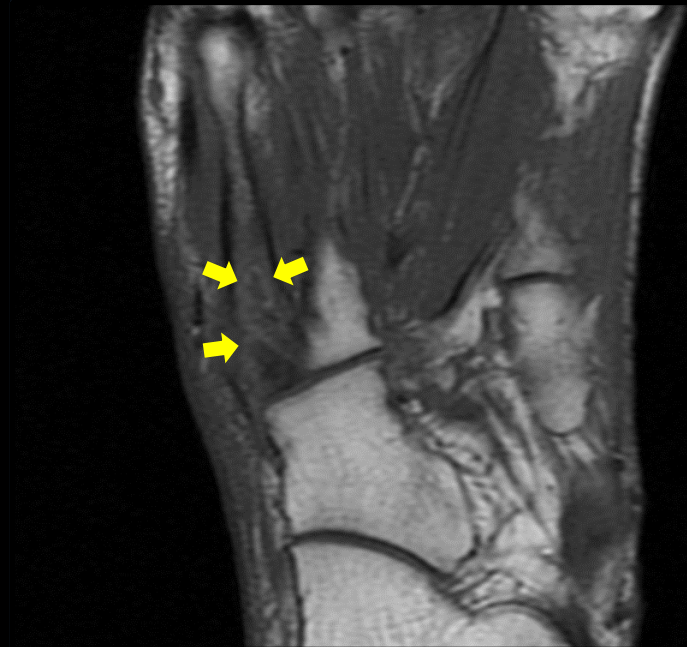


STIR sagi

初回から1ヶ月後の右足の単純MRI



T1WI 矢状断



T1WI 軸位断