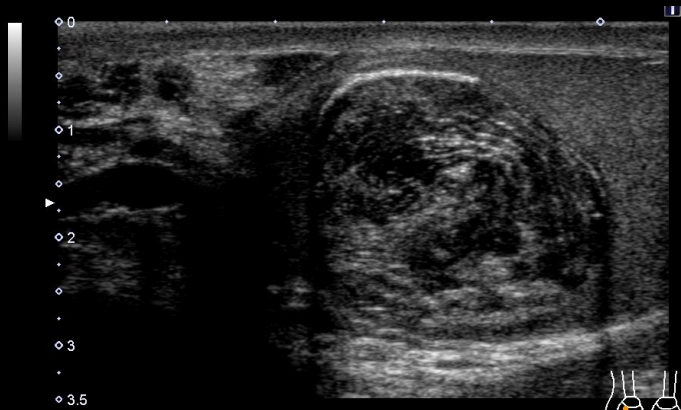
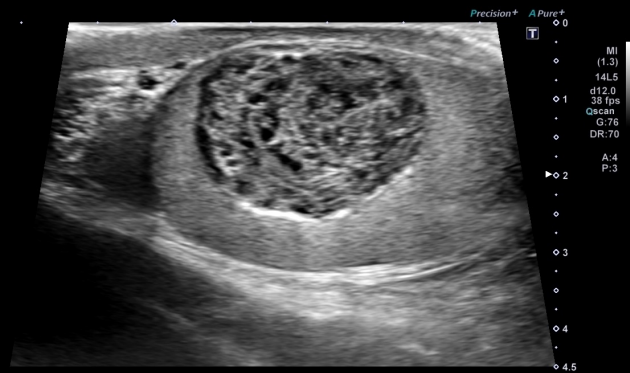
初診時



2.5年後

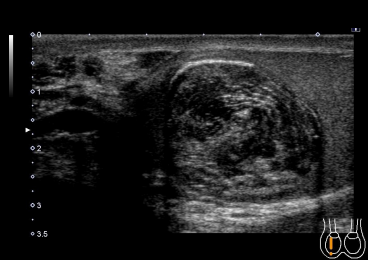


図1：US Bモード

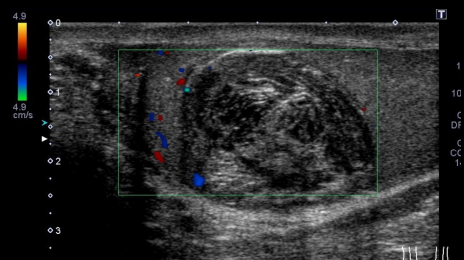


図2：US カラー Doppler 法

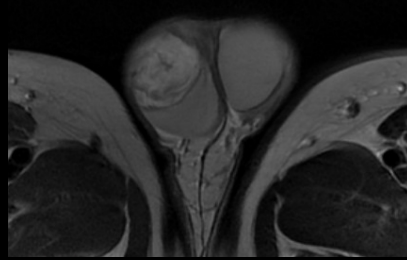


図3：MRI T2強調像

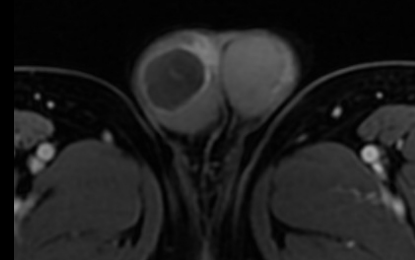


図4：MRI 造脂肪抑制T1強調像

