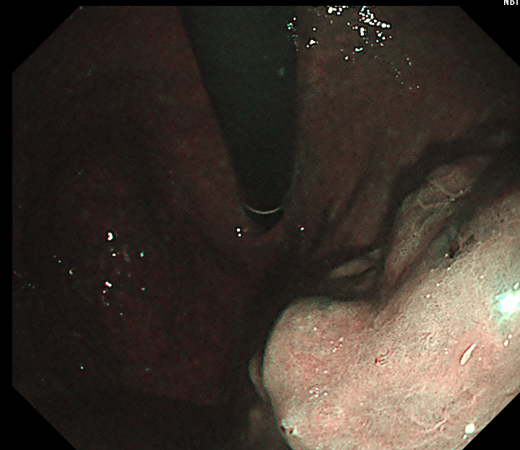
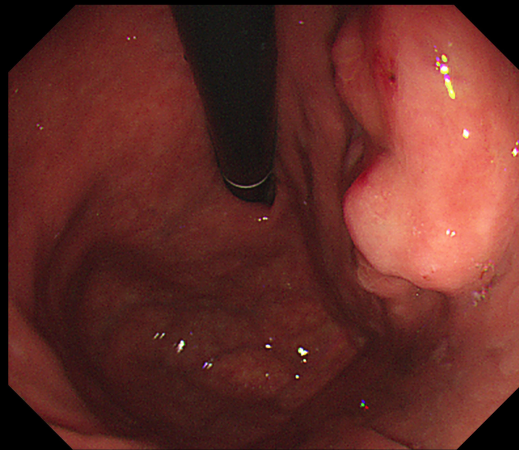


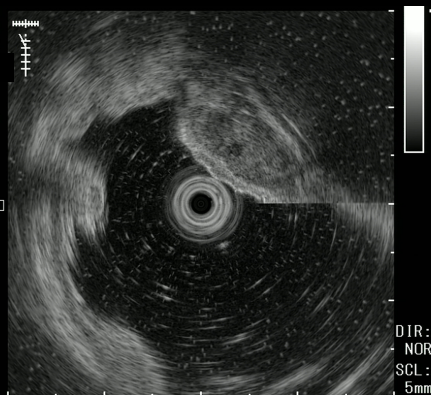
来院時内視鏡所見



0 79
S 16/03/ F
11:45:00
20MHz 4cm
G: 13/19 1:1
C: 4/8

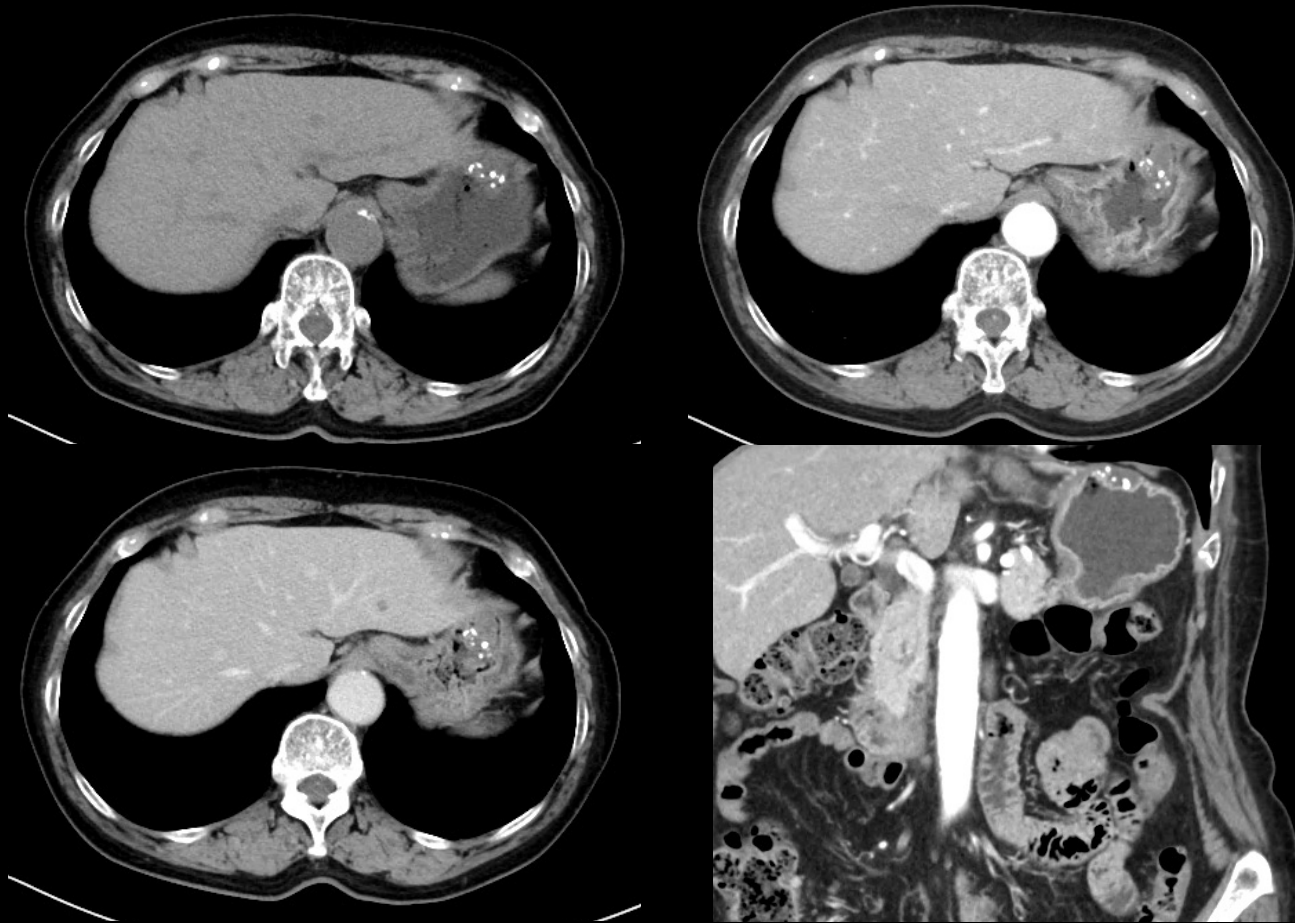MEDIA
T/B: NONE
8/ 12
+: mm
x: mm
o: mm
Δ: mm

CNCT: R



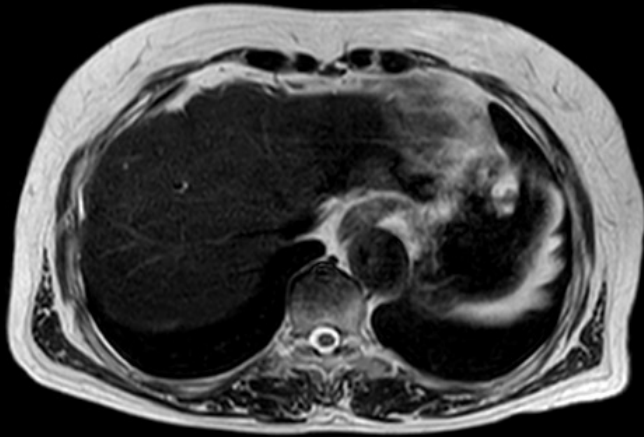
DIR:
NOR
SCL:
5mm

Key image(来院時腹部造影CT)

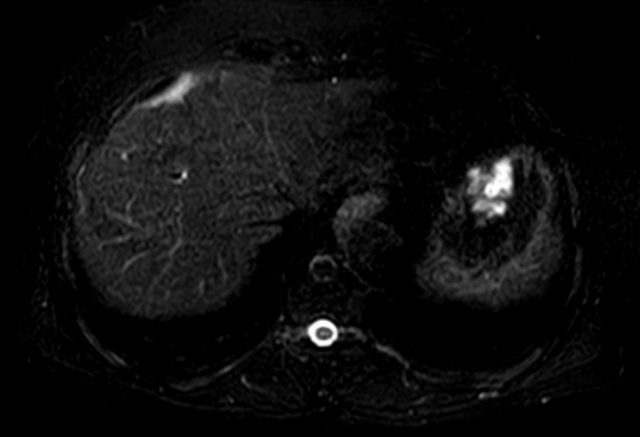


Key image(非造影MRI)

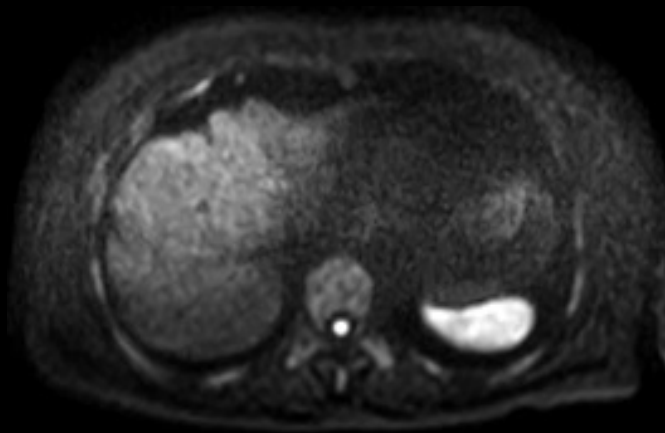
T2WI



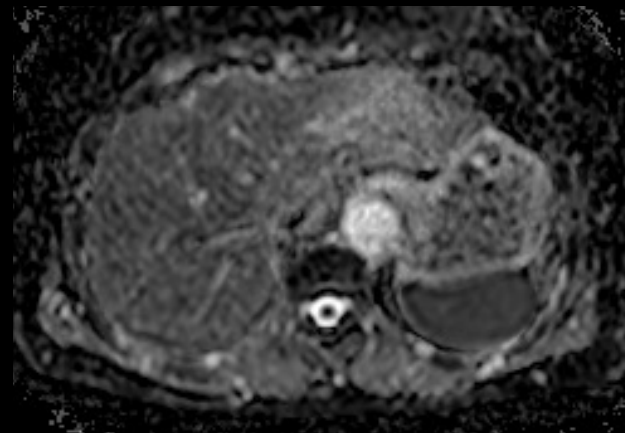
脂肪抑制T2WI



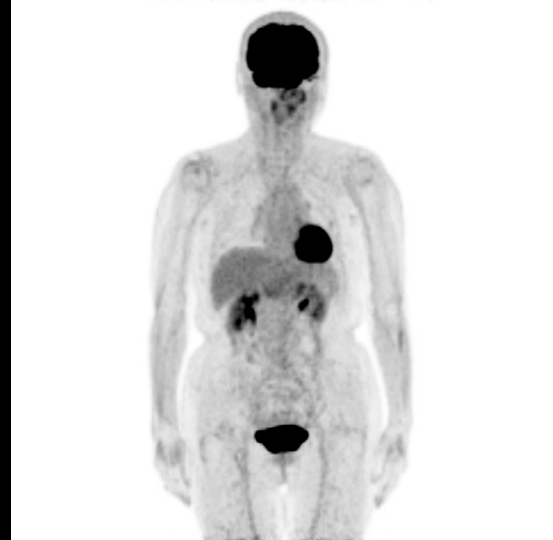
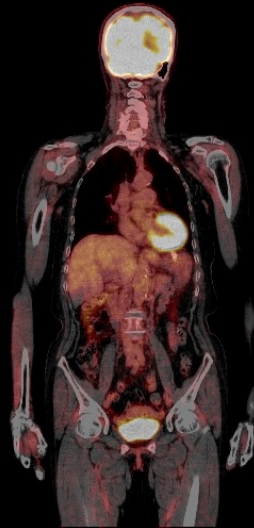
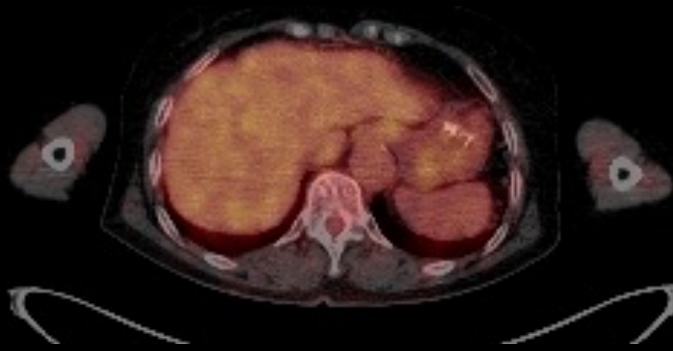
DWI



ADCmap



Key image (FDG-PET/CT)



Key image(上部消化管造影)

