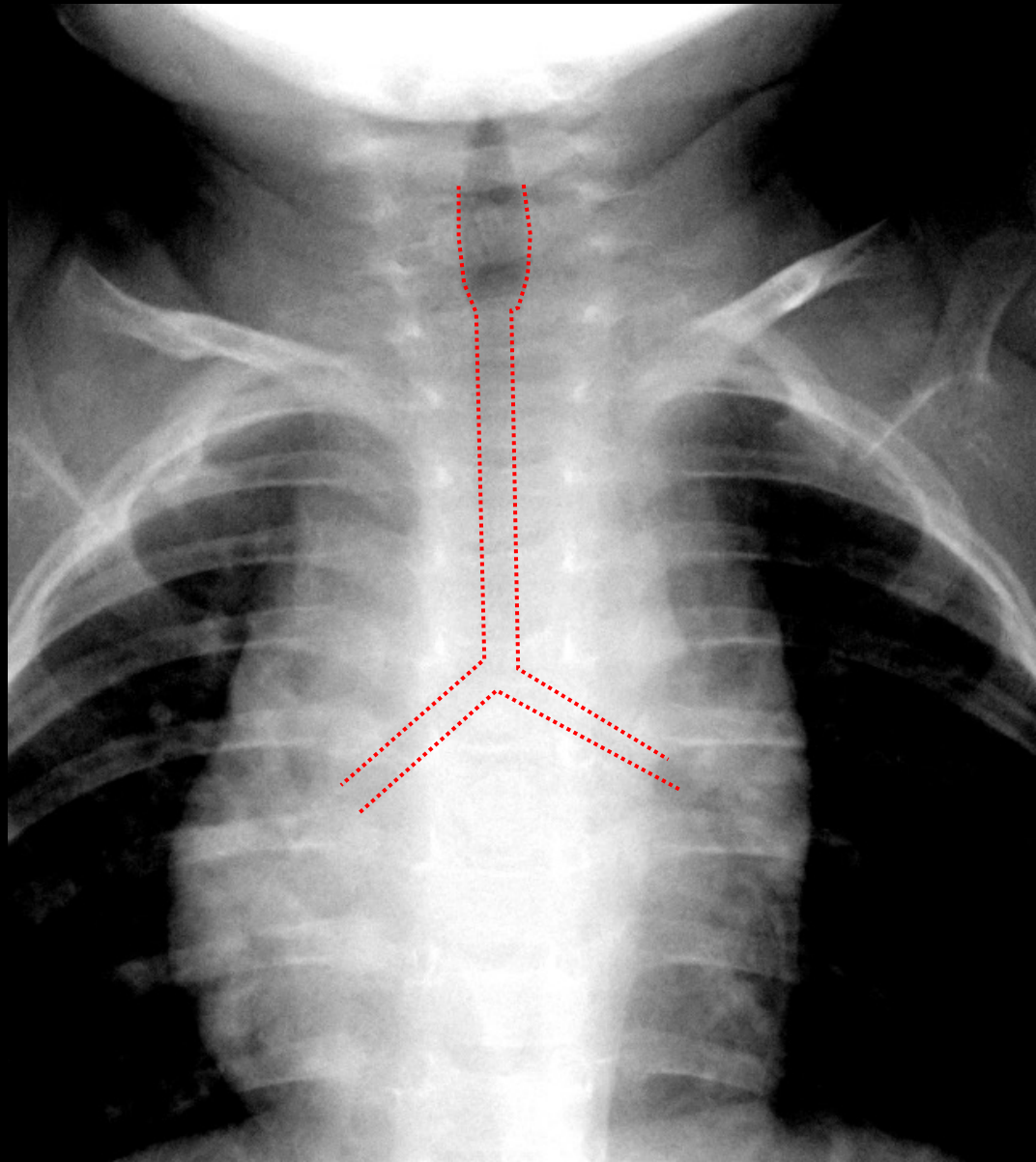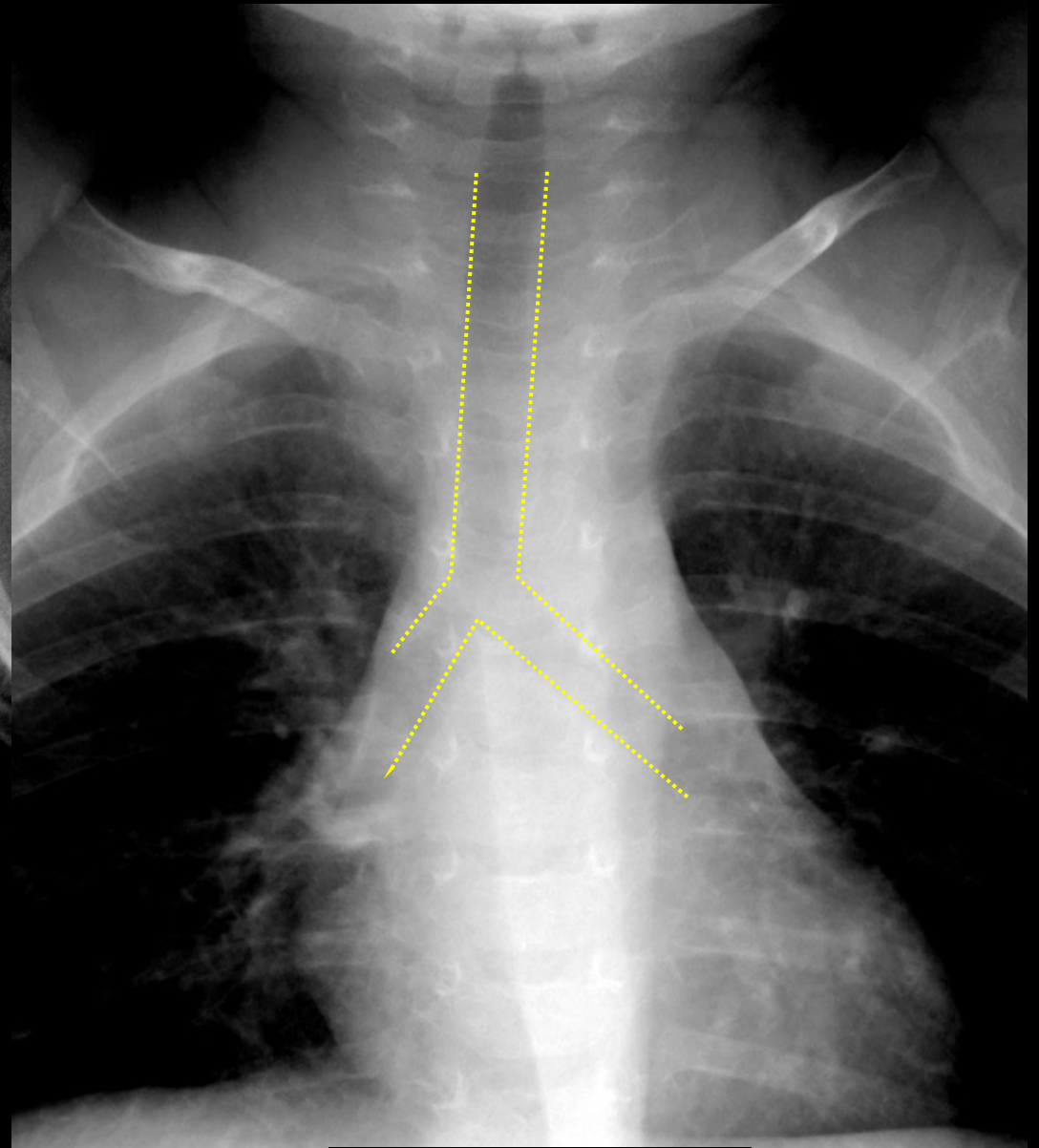
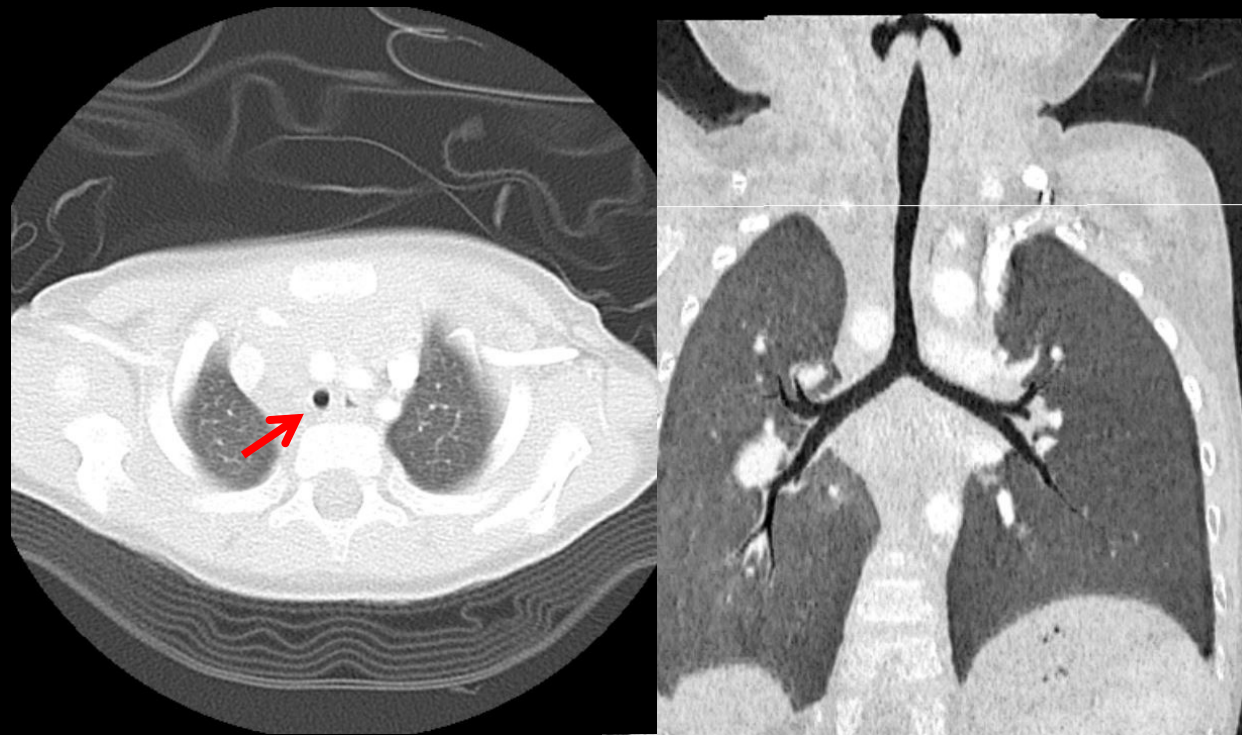


本症例



同月齡 正常児

造影CT



縦隔CT

